

# SUCCESSFUL TREATMENT OF A CHRONIC VENOUS ULCER WITH A SILVER CONTACT DRESSING AND COMPRESSION THERAPY

*Carol Publicover MSN, ARNP, CWOCN, Florida Hospital Wound Management Centers, Orlando, Florida*

## PURPOSE

To evaluate the healing process associated with the use of a silver contact dressing (Silverlon) and compression therapy (Unna boot).

## HISTORY

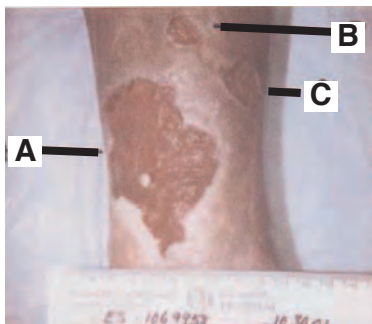
A 53 year old male with diabetes, peripheral vascular disease, and a nonhealing lower extremity venous stasis ulcer with associated intractable edema. He reports 6 years of treatment with multiple wound care modalities, none of which have produced 100% healing.

## CURRENT CLINICAL APPROACH (Effective 10/30/01)

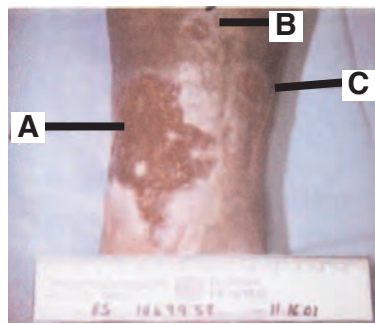
The wounds were cleansed and debrided as appropriate. The periwound was protected with skin barrier. A silver dressing (Silverlon) was moistened with sterile water and applied to the wound surface. A secondary dressing was applied followed by compression therapy. Dressings were changed twice weekly x5 then weekly until closure.

## SUMMARY

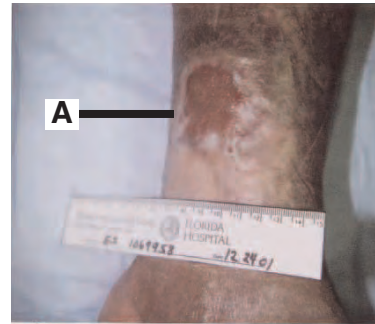Despite a significant medical history and multiple treatment failures, the wounds completely healed in 17 weeks, with a dramatic reduction in pain.



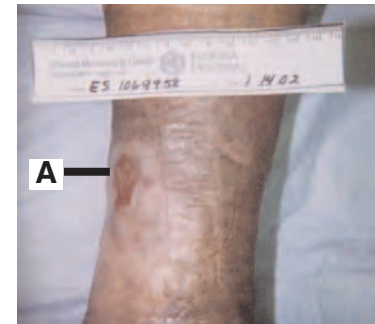10/30/01  
A = 9.0 x 7.4 cm  
B = 1.3 x 1.6 cm  
C = 2.0 x 2.2 cm



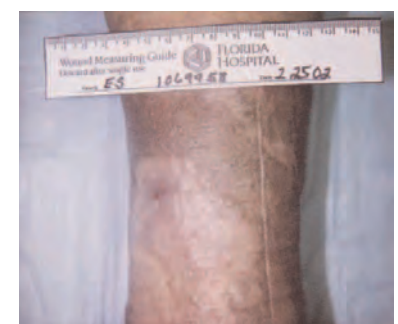11/16/01  
A = 7.0 x 6.6 cm  
B = Healed  
C = 0.7 x 1.3 cm



12/24/01  
A = 3.0 x 3.5 cm  
C = Healed



1/14/02  
A = 2.4 x 1.8 cm



2/25/02  
A = Healed