endoform®

CLINICAL EVIDENCE | Treatment of Diabetic Foot Ulcers (DFUs)

Endoform® helps reduce the time, cost and complication of closing diabetic foot ulcers

- Treating DFUs with **Endoform®** following debridement can lead to 90% wound closure by 12 weeks and complete closure in 24 weeks. [1]
- Using **Endoform®** as the first-line intervention increased the healing rate and reduced healing time and cost compared with cellular and tissue-based products (CTPs) alone. [2]
- Wound management with **Endoform®** from day one can eliminate the need for CTPs. [3]
- **Endoform®**, along with gentian violet/ methylene blue (GV/MB) and hyperbaric oxygen therapy (HBOT) can lead to favourable outcomes in high risk diabetic patients (> Wagner grade 3). [4]
- **Endoform®** in combination with negative pressure wound therapy (NPWT) may contribute to limb salvage after surgical intervention in high risk DFUs [5]
- **Endoform®** in combination with NPWT helped to reduce the average wound closure time by 10 days compared to NPWT alone in a clinical study. [6]
- **Endoform®** helps advance stalled wounds to closure by optimizing the wound healing environment. [7]
- **Endoform®**, in combination with GV/MB, may lead to reduced bioburden and matrix metalloproteinase's (MMPs) in the wound, as well as patient satisfaction and compliance. [9,8]
- **Endoform®** tackles complex wounds (e.g. exposed bone and tendon), providing complete tendon coverage and leading to closure without complications. [3,10,11,12]

Week 0:

Wound measurement:
0.8 cm x 0.7 cm x 0.7 cm

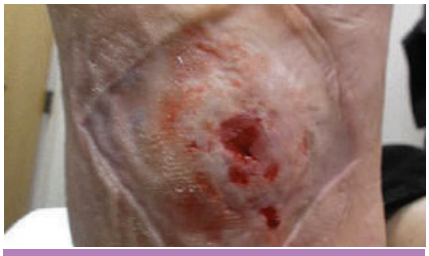

Week 5:

Wound measurement:
Wound size decreased with healthy granulating tissues

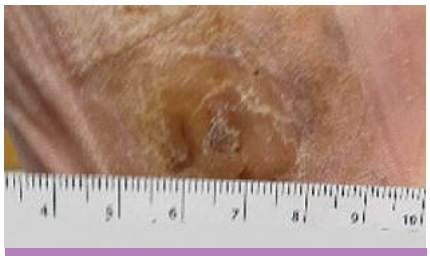

Week 8:

Wound measurement:
100% re-epithelialized

Closure of 6-month old wound in 56-year old patient [8]

Endoform® can be used at all phases of wound management

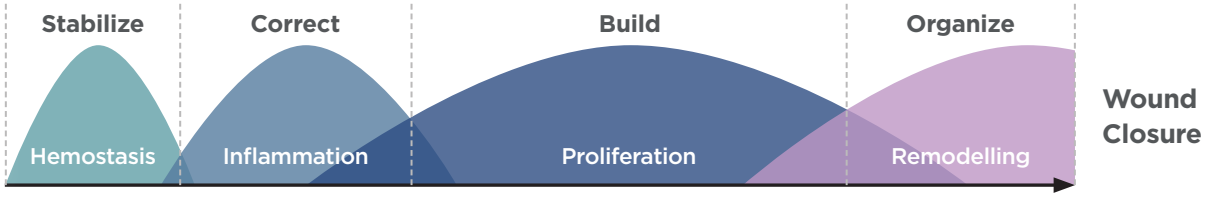

endoform®

CLINICAL EVIDENCE | Treatment of Diabetic Foot Ulcers (DFUs)

References

1. Lullove, E. J. (2017). "Use of Ovine-based Collagen Extracellular Matrix and Gentian Violet/Methylene Blue Antibacterial Foam Dressings to Help Improve Clinical Outcomes in Lower Extremity Wounds: A Retrospective Cohort Study." Wounds 29(4): 107-114. **2.** Fleck, K. A., T. Reyes and H. C. Wishall (2018). Effect of Ovine-Based Collagen Extracellular Matrix Dressings on Outcomes in an Outpatient Wound Care Center. Society for Advanced Wound Care - Spring, Charlotte, NC. **3.** Roith_xxxx Treating diabetic foot ulcers patients with CECM prior to cellular tissue products. **4.** McIlrath, P. and J. T. Wattlers (2017). The Use of Ovine Collagen Extracellular Matrix and Gentin Violet and Methylene Blue Antibacterial Foam Dressings in the Effective Treatment of Wounds with Exposed Tendon and Bone in the High Risk Diabetic Foot. Society for Advanced Wound Care - Spring, San Diego, CA.
5. Silverman, A. (2017). Use of an Ovine Collagen with an Intact Extracellular Matrix (CECM) and negative pressure wound therapy (NPWT) as part of the wound management plan following limb salvage surgical intervention in high risk diabetic foot ulcers. Symposium on Advanced Wound Care - Spring, San Diego, CA. **6.** Vidovic, G. and P. Sykes (2016). The use of an ovine collagen extracellular matrix dressing in conjunction with negative pressure wound therapy in the management of chronic diabetic foot ulcers. Symposium on Advanced Wound Care - Fall, Los Vegas, NA. **7.** Wright, K., D. Hastings, W. Dukes and K. Gorgui (2013). Innovative Dressing Option: Use of a collagen dermal template with extracellular matrix (ECM)* in the management of lower extremity wounds. Clinical Symposium on Advances in Skin & Wound Care, Orlanda, FL. **8.** Roith, J. (2016). Managing Diabetic Foot Ulcers Using a Three Pronged Approach: V.I.P. Symposium for Advanced Wound Care - Fall, Las Vegas, NA. **9.** Zilberman, I. and N. Zolfaghari (2014). Use of ovine collagen extracellular matrix (CECM) dressing and gentian violet and methylene blue (GV/MB) antimicrobial foam dressing in the management of diabetic foot ulcers. The Symposium on Advanced Wound Care - Fall. Las Vegas, NA. **10.** Zilberman, I. and N. Zolfaghari (2016). Innovative solutions in the management of wounds with exposed tendons utilizing ovine collagen extracellular matrix and gentian violet and methylene blue antibacterial foams. Symposium on Advanced Wound Care - Atlanta, GA. **11.** Lullove, E. (2015). Case Study 18: Dorsal Diabetic Foot Ulcer, Hollister Incorporated.
12. Zilberman, I. (2015). Case Study 20: Diabetic Foot Ulcer + Left First Metatarsal, Hollister Incorporated.

endoform®

Natural Dermal Template

endoform®

Antimicrobial Dermal Template

RX Only. Prior to use, be sure to read the entire Instructions for Use package insert supplied with the product.

For product questions, sampling needs, or detailed clinical questions concerning our products in the US, please call 1-860-337-7730

HCPCS are for reference only and subject to change.

Appulse

Endoform® Dermal Template is marketed in the USA by Appulse

AROA

Manufactured for:
AROA BIOSURGERY INC
340 Progress Drive, Manchester, CT 06042
1-860-337-7730
www.aroabio.com

MKT 1421.01 | May 2018

Wounds. 2017 Apr;29(4):107-114.

Use of Ovine-based Collagen Extracellular Matrix and Gentian Violet/Methylene Blue Antibacterial Foam Dressings to Help Improve Clinical Outcomes in Lower Extremity Wounds: A Retrospective Cohort Study.

Lullove EJ[1].

Author information

Abstract

Dressings that provide broad spectrum metalloprotease reduction along with inherent aspects of an extracellular matrix may contribute to improved wound healing outcomes and shorter treatment times.

OBJECTIVE: The author performed a retrospective case series analysis to determine the clinical outcomes of regular debridement with the use of ovine-based collagen extracellular matrix dressings and gentian violet/methylene blue polyurethane antibacterial foam dressings in treating 53 patients with 53 chronic lower extremity wounds (diabetic foot ulcers [DFUs], venous leg ulcers, and heel pressure ulcers).

MATERIALS AND METHODS: Patients were treated twice weekly in an outpatient clinic for the first 4 weeks and weekly thereafter until closure.

RESULTS: Average body mass index (BMI) for the study population was 28.3, and the average patient age was 75.9 years. Mean percent wound surface area reduction at 4, 8, and 12 weeks was 38.5%, 73.3%, and 91.3%, respectively. Average time to closure for all wounds was 10.6 weeks (range, 5-24 weeks). All wounds were 100% reepithelialized by week 20 except 1 DFU that reepithelialized at week 24. The average cost of care for a single wound episode (from presentation to closure) was $2749.49.

CONCLUSION: Results of this analysis showed that the healing of chronic wounds in this series could be achieved at a reasonable cost with regular debridement and a collagen matrix dressing regimen, even in patients of advanced age and above average BMI as well as in wounds that did not achieve > 40% wound surface area reduction at 4 weeks.

PMID: 28448264

[Indexed for MEDLINE]

Effect of Ovine-Based Collagen Extracellular Matrix Dressings on Outcomes in an Outpatient Wound Care Center.

• Karen A. Fleck, MD • Teresa Reyes • Hunter C. Wishall
Baptist Medical Center Jacksonville – Center for Wound Care and Hyperbaric Medicine

Introduction:

- Cost efficiency in today's stringent healthcare arena requires appropriate and judicious use of advanced therapies such as cellular and/or tissue based products (CTPs) for chronic wound management.
- Evidence has linked dermal graft (CTP) failure to elevated matrix metalloproteinase (MMP) levels in diabetic foot ulcers (DFUs),[1] thus suggesting that protease balance for the purpose of wound bed preparation prior to CTP placement should be a clinical priority.
- An ovine-based collagen extracellular matrix (CECM) dressing,* available as a HCPCS A-code,[2] with an intact extracellular matrix has demonstrated broad-spectrum MMP reduction.[3]
  Results from several case series also suggest that CECM dressings may play a positive role in wound healing.[4-6]
- Considering the high cost of CTP failure - not only in expenditure for the CTP, but also in lengthened time to heal due to the failure - and the fact that there are no visual, clinical signs related to elevated MMPs,[1] we decided to take a proactive approach by implementing a CECM dressing as the first line dressing to treat chronic wounds.

Purpose:

To evaluate the change in CTP usage and wound healing outcomes in chronic wounds, specifically DFUs and VLUs, following the implementation of a CECM dressing as the first-line conventional wound treatment strategy in an outpatient wound care center.

Methodology:

- Records from two years (April 2015 to March 2017) were retrospectively reviewed to determine total number and healing rate of venous leg ulcers and diabetic foot ulcers that were treated by one physician investigator in an outpatient wound clinic.
- Calculations of the actual number of wounds treated by one physician investigator included only DFUs and VLUs since they made up the majority of wounds treated at the center. Additional wound types were treated during the study time frame, but for the sake of simplicity, they were not accounted for in this analysis.
- CECM dressing expenditures were estimated by multiplying the wound center's total CECM dressing expenditures by the percentage of wounds treated by the single investigator compared to the wound center's total number of wounds treated. The investigator's actual CECM dressing unit usage was not recorded or available.

Table 1. Demographics and outcomes

	Year 1	Year 2	Increase/Decrease from Year 1 to Year 2
Total chronic wounds treated (n)	109	159	45.9%
DFUs treated (n)	51	87	70.6%
VLUs treated (n)	58	72	24.1%
DFUs healed	45 (87.3%)	83 (96.2%)	10.2%
VLUs healed	55 (95.8%)	71 (98.8%)	03.1%
Average time to healing DFU (days)	29.5	21	-28.8%
Average time to healing VLU (days)	23.1	27.1	17.3%
CTP use (units)	34	11	-67.6%
CTP expenditure ($)	42,320	13,764	-67.5%
CECM expenditure ($)	0	9,718	--
Total CTP and CECM expenditures ($)	42,320	23,482	-44.5%

Figure 1. CTP and CECM expenditures: Year 1 vs Year 2

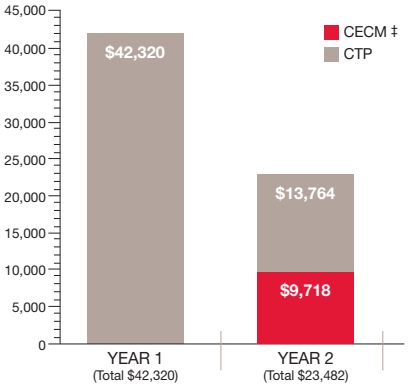

‡ Incorporation of CECM dressings as first-line conventional treatment strategy

Figure 2. DFUs and VLUs treated and outcomes Year 1 vs Year 2

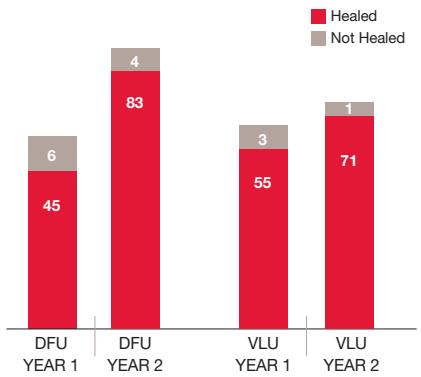

A healed wound was defined as 100% re-epithelialized with no drainage; total CTP and CECM dressing expenditures were dollar amounts invoiced to the institution for the dressings.

- Number of wounds treated, wound healing rate, and monthly expenditures for CTP and collagen dressings were compared between the 12 months prior to incorporation of CECM dressings (Year 1: April 1, 2015 - March 31, 2016) versus the 12 months after incorporation of CECM dressings (Year 2: April 1, 2016 - March 31, 2017).

Results:

- A total of 109 chronic wounds (51 diabetic foot ulcers [DFUs] and 58 venous leg ulcers [VLUs]) were treated in Year 1 and 159 wounds (87 DFUs and 72 VLUs) were treated during Year 2.
- Average time to healing for DFUs was 29.5 days during Year 1 versus 21.0 days in Year 2. For VLUs, the average time to healing was 23.1 days in Year 1 and 27.1 days in Year 2.
- Forty-five of 51 (87.3%) DFUs healed in Year 1 and 83/87 (96.2%) of DFUs healed in Year 2, while 55/58 (95.8%) VLUs healed in Year 1 and 71/72 (98.8%) VLUs healed in Year 2.
- CTP unit usage decreased by 67.6% (34 units to 11 units) from Year 1 to Year 2. In regard to total expenditures, in Year 2 the CTP and CECM dressing expenditures totaled $23,482, which represented a 44.5% decrease from Year 1, despite an increase in number of wounds treated.

Conclusion:

Results of this analysis displayed a trend toward decreased expenditures, while maintaining similar healing rates for DFUs and VLUs with the use of a CECM dressing as the first-line chronic wound treatment protocol in a wound care center.

References:

1. Izzo, Valentina & Meloni, Marco & Vainieri, Erika & Giurato, Laura & Ruotolo, Valeria & Uccioli, Luigi.. High Matrix Metalloproteinase Levels Are Associated With Dermal Graft Failure in Diabetic Foot Ulcers. The international journal of lower extremity wounds. 2014, Vol. 13(3) 191 –196
2. www.dmepdac.com: A6021-24, October 13, 2017
3. Negron L, Lun S, May BC. Ovine forestomach matrix biomaterial is a broad spectrum inhibitor of matrix metalloproteinases and neutrophil elastase. Int Wound J. 2014;11:392-7.
4. Liden BA, May BC. Clinical outcomes following the use of ovine forestomach matrix (endoform dermal template) to treat chronic wounds. Adv Skin Wound Care 2013;26(4):164-7.
5. Ferreras DT, Craig S, Malcomb R. Use of an Ovine Collagen Dressing with Intact Extracellular Matrix to Improve Wound Closure Times and Reduce Expenditures in a US Military Veteran Hospital Outpatient Wound Center. Surg Technol Int. 2017 May 24;30.
6. Lullove EL. Use of Ovine-based Collagen Extracellular Matrix and Gentian Violet/Methylene Blue Antibacterial Foam Dressings to Help Improve Clinical Outcomes in Lower Extremity Wounds: A Retrospective Cohort Study. Wounds. 2017 Apr;29(4):107-114.

*Endoform dermal template, Hollister Incorporated, Libertyville, IL

The author received an honorarium from Hollister Incorporated.

Appulse

Fleck, K. A., T. Reyes and H. C. Wishall (2018). Effect of Ovine-Based Collagen Extracellular Matrix Dressings on Outcomes in an Outpatient Wound Care Center. Society for Advanced Wound Care - Spring, Charlotte, NC

Manufactured for:
AROA BIOSURGERY INC
340 Progress Drive, Manchester, CT
06042
1-860-337-7730
www.aroabio.com

AROA

Treating Diabetic Foot Ulcer Patients with an Ovine Collagen Extra Cellular Matrix Prior to Cellular Tissue Products.

Overland Park, KS

• Jeffrey Roith, DPM • Tina Neill, RN

Introduction:

Diabetic foot ulcers are the most expensive type of chronic ulcer to heal; almost twice the cost of other ulcers.[1] Wound healing requires a balance of matrix metalloproteinases (MMPs) and tissue inhibitors of metalloproteinases (TIMPs). Diabetic foot ulcers were found to have excess MMPs and decreased TIMPs which may contribute to diabetic ulcers not healing.[2]

Purpose:

Utilizing an ovine collagen that has an intact extra cellular matrix (CECM)[3] and broad spectrum MMP reducing ability[4] before turning to cellular tissue products (CTP), may reduce the cost of diabetic foot ulcer treatment and in some cases may eliminate the need to use CTP.

Materials and Methods:

An elderly patient with multiple comorbidities and a previous diabetic foot ulcer, presented to the podiatrist office with a reopened right plantar ulcer. Ulcer was debrided and CECM treatment initiated while waiting for insurance approval of a cellular tissue product. CECM was applied according to instructions for use and was covered with a bordered foam dressing and changed every three days.

Results:

Wound was debrided at the first visit. Post debridement wound measured 0.7cm x 0.4cm x 0.1cm, CECM dressing was initiated. Wound size progressively decreased and achieved 100% epithelization in eight weeks, before CTP was approved.

Conclusions:

Ovine collagen is a wound dressing that has a native intact ECM and broad spectrum MMP reduction. Clinicians can use on day one usually without insurance approval to treat diabetic foot ulcers. CECM is classified with an "A" code under the surgical dressing policy and not a Q code, therefore prescribing clinicians can order product for patients in all care settings. Initial treatment with CECM prepares the wound bed by decreasing MMPs while providing an ECM. Utilizing a CECM dressing before turning to more expensive options offers clinicians a cost effective alternative to treat diabetic foot ulcers.

REFERENCES

1. Vollmer PM, et al. (2012) Wound Care Outcomes and Associated Cost Among Patients Treated in US Outpatient Wound Centers: Data From the US Wound Registry. WOUNDS, 24(6):[illegible]
2. Lobmann, R., et al, (2002). Expression of matrix-metalloproteinases and their inhibitors in the wounds of diabetic and non-diabetic patients. Diabetologia, (45), 1011–1016-1011–1016. doi:DOI 10.1007/s00125-002-0868-8
3. Endoform brochure, Hollister, Inc.
4. Negron L, Lun S, May BC. Ovine forestomach matrix biomaterial is a broad spectrum inhibitor of matrix metalloproteinases and neutrophil elastase. Int Wound J. 2012 Nov 1.

Day 1: Post debridement

Day 31

Day 9

Day 43

Day 16

Day 57

Appulse

Roith J. (2015) Treating diabetic foot ulcers patients with CECM prior to cellular tissue products. Annual High Risk Diabetic Foot Conference, Pheonix, AZ

Manufactured for:
AROA BIOSURGERY INC
340 Progress Drive,
Manchester, CT 06042
1-860-337-7730
www.aroabio.com

AROA

The Use of Ovine Collagen Extracellular Matrix and Gentian Violet and Methylene Blue Antibacterial Foam Dressings in the Effective Treatment of Wounds with Exposed Tendon and Bone in the High Risk Diabetic Foot

• Patricia McIlrath, DPM • Jane T. Wattlers RN, BSN, WCC
Temple University Hospital - Wound Care and Hyperbarics

Objective:

Demonstrate the use of ovine collagen extracellular matrix (CECM)* and gentian violet/methylene blue (GV/MB) antibacterial foam dressings as an adjunct therapy in the treatment of wounds with exposed tendon and bone in diabetic limbs.

Introduction:

Diabetes has become more prevalent in our society, affecting 29.3 million Americans and more than 415 million people worldwide.[1] If Diabetes was a country, it would be the 3rd largest in the world.[2] An estimated 15% of patients with diabetes will develop a lower extremity ulcer during the course of their disease.[3,4] Foot ulcerations are the precursor to many lower leg amputations in persons with diabetes. This is a large concern in the care of the diabetic. The field of wound care is ever expanding with many advances in technology. Advanced modalities such as skin substitutes, biologic wound products and growth factors help facilitate healing.[5] There are other wound care dressings, such as CECM with an extracellular matrix (ECM), that help promote tissue granulation[6] and provide a temporary scaffold to help cells migrate, leading to tissue epithelialization for final wound closure.[7,8] GV/MB antibacterial foam dressings may support autolytic debridement. [9,10] The broad-spectrum antibacterial activity helps provide bioburden management and the dressing helps maintain moisture balance.[9,10] Tendon and/or bone exposure in a wound increases the complexity and provides challenges in healing the wound. These severe wounds may increase the likelihood of amputation, therefore requiring the need for aggressive and advanced wound care.

Methods:

These cases involve high risk diabetic patients with diabetic foot ulcers (DFUs) that were Wagner 3 or greater, with tendons and/or bone exposed. The wounds were surgically debrided, patients placed on IV antibiotics, and advanced wound care modalities such as hyperbaric oxygen therapy (HBOT) were used, in conjunction with CECM to prepare the wound bed for more advanced modalities. GV/MB polyvinyl alcohol (PVA)** antibacterial foam dressing was used to support autolytic debridement and reduction of biofilm. GV/MB polyurethane (PU)*** antibacterial foam dressing was also used depending on exudate level of wound. CECM was used prior to skin graft placement and again two weeks after skin graft to complete healing. Dressings were removed prior to HBOT weekly therapy.

Conclusion:

In the cases provided, the combination of CECM and GV/MB antibacterial foam dressings were implemented throughout the entire course of treatment. This form of treatment showed favorable results in preparation of these wounds with exposed tendon and/or bone. This wound care management approach in conjunction with other modalities, skin grafts and skin substitute application was also shown to be favorable.

Case Study 1

Patient: 63 year-old male presented with skin graft with exposed bone after a great toe amputation

Past medical history:

- Diabetes, hypertension, gangrene

Initial Visit Wound measurement:
4.0 cm x 4.0 cm x 1.5 cm
Wound Description:
Non-healing chronic full thickness surgical wound with muscle and bone exposed, large amount of sanguineous drainage.

Week 2 Wound measurement:
6.0 cm X 6.5 cm X 0.4 cm
Wound Description:
Wound has granulation tissue with little auto skin graft incorporated
Wound Management:
CECM applied to wound bed covered by GV/MB PVA antibacterial foam dressing and HBOT

Week 5 Wound measurement:
6.6 cm X 4.0 cm X 0.2 cm
(before sutures were placed)
Wound Description:
Wound sutured together after debridement
Wound Management:
CECM applied to wound bed covered by GV/MB PU antibacterial foam dressing and HBOT

Week 9 Wound measurement:
0.1 cm X 0.1 cm X 0.1 cm
Wound Description:
Small granular area
Wound Management:
CECM applied to wound bed in area of exposed tissue covered by GV/MB PU antibacterial foam dressing and HBOT

Week 10
Wound closure

REFERENCES
1. International Diabetes Federation. IDF Diabetes Atlas, 7th edn. Brussels, Belgium: International Diabetes Federation, 2015.
2. 2015 UN World population prospects; International Diabetes Federation
3. Frykberg, Robert G., et al. "Diabetic foot disorders: a clinical practice guideline (2006 revision)." The journal of foot and ankle surgery 45.5 (2006): S1-S66.
4. Reiber, G. E., Boyko, E. J., & Smith, D. G. (1995). Lower extremity foot ulcers and amputations in diabetes. Diabetes in America, 2, 409-427.
5. Murphy, Patrick S. , Gregory, R.D. (2012). Advances in Wound Healing: A Review of Current Wound Healing Products. Plastic Surgery International, Vol 2012, ID 190436
6. Tonnesen MG et al. Angiogenesis in Wound Healing, The Society for Investigative Dermatology, Inc. Vol 5, 1; 2000.
7. Pastar I et al. Epithelialization in Wound Healing: A Comprehensive Review. Adv in Skin and Wound Care, Vol 3, 7; 2014.
8. International Consensus: Acellular Matrices for the Treatment of Wounds. Wounds International. 2016.
9. Sibbald RG, Ovington L, Ayello E, Goodman L, Elliott J. Wound bed preparation 2014 update: management of critical colonization with a gentian violet and methylene blue absorbent antibacterial dressing and elevated levels of matrix metalloproteases with an ovine collagen extracellular matrix dressing. Advances Skin Wound Care 2014; 27(3) s1-6.
10. Edwards K. New twist on an old favorite: gentian violet and methylene blue antibacterial foam dressings. Adv Wound Care (New Rochelle). 2015.

*Endoform™ dermal template - Distributed by Hollister Incorporated.
**Hydrofera Blue™ classic foam dressing - Distributed by Hollister Incorporated.
***Hydrofera Blue READY™ foam dressing - Distributed by Hollister Incorporated.
Financial Disclosure: The author received an honorarium from Hollister Incorporated.

Case Study 2

Patient: 57 year-old male status post-amputation to the right 4th and 5th toes/rays

Past medical history:

- Type II diabetes, heart disease, hypertension, congestive heart failure

Initial Visit Wound measurement:
8.5 cm x 2.4 cm x 0.6 cm
Wound Description:
Wound dehisced with sutures intact
Wound Management:
No previous wound care

Week 1 Wound measurement:
8.5 cm X 2.4 cm X 0.8 cm
Wound Description:
Fibrotic tissue at the distal aspect of the wound with depth and probing to bone; little granulation; moderate drainage
Wound Management:
Collagenase covered by GV/MB PVA antibacterial foam dressing for one month. Changed to CECM applied to wound bed covered by GV/MB PVA antibacterial foam dressing and HBOT. Applied 1-2 times per week

Week 6 Wound measurement:
3.4 cm X 1.2 cm X 0.3 cm
Wound Description:
Wound remains fibrotic and can still probe to bone
Wound Management:
Debridement, CECM applied to wound bed covered by GV/MB PVA antibacterial foam dressing and HBOT

Week 10 Wound measurement:
3.0 cm X 1.0 cm X 0.3 cm
Wound Description:
Fibrotic and granulation tissue
Wound Management:
Application of cellular tissue product (CTP) every other week. Application of CECM in between CTP applications covered by non-adherent dressing and a dry sterile dressing secured with rolled gauze

Week 15 Wound measurement:
2.0 cm X 0.5 cm X 0.1 cm
Wound Description:
No exposed bone and no longer able to probe to bone, no fibrotic tissue, and granular base
Wound Management:
Continued with previous protocol

Week 21
Wound closure

Case Study 3

Patient: 46 year-old male right foot non-healing wound

Past medical history:

- Type II diabetes, hypertension, end stage renal disease, hemodialysis

Initial Visit Pre-debridement :
12.0 cm X 5.5 cm X 0.3 cm
Wound Description:
Fibrotic tissue at the center with bone and tendon exposed. X-rays are consistent with osteomyelitis. Patient refused a below knee amputation
Wound Management:
Debridement, collagenase and HBOT

Initial Visit Post-debridement :
12.0 cm X 6.0 cm X 0.3 cm

Week 4 Wound measurement:
9.4 cm X 4.2 cm x 0.3 cm
Wound Description:
Granulation tissue with exposed tendons and bone at the center
Wound Management:
Debridement, CECM covered by a non-adherent with NPWT changed twice weekly and with daily HBOT

Week 7 Wound measurement:
9.0 cm X 4.0 cm X 0.2 cm
Wound Description:
Wound bed is 100% granular
Wound Management:
Discontinued NPWT. Debridement, CECM applied to wound bed covered by GV/MB PVA antibacterial foam dressing and HBOT

Week 12 Wound measurement:
7.0 cm X 3.5 cm X 0.2 cm
Wound Description:
100% granulation tissue, no exposed tendons or bone
Wound Management:
Debridement, CECM applied to wound bed covered by GV/MB PVA antibacterial foam dressing and HBOT

Week 14 Wound measurement:
6.5 cm X 3.3 cm X 0.2 cm
Wound Description:
100% granulation tissue
Wound Management:
Application of CTP every 2-3 weeks using CECM applied to wound bed covered by GV/MB PU antibacterial foam dressing in between application of the CTP with HBOT

Week 17 Wound measurement:
4.0 cm X 2.0 cm X 0.1 cm
Wound Description:
100% granulation tissue
Wound Management:
Continued application of CTP every 2-3 weeks using CECM applied to wound bed covered by GV/MB PU antibacterial foam dressing in between applications of the CTP with HBOT

Week 18 Wound measurement:
3.0 cm X 1.5 cm X 0.1 cm
Wound Description:
100% granulation tissue. Wound size reduction of 93.75%
Wound Management:
Continued application of CTP every 2-3 weeks using CECM applied to wound bed covered by GV/MB PU antibacterial foam dressing in between application of the CTP with HBOT

Appulse

McIlrath, P. and J. T. Wattlers (2017). The Use of Ovine Collagen Extracellular Matrix and Gentin Violet and Methylene Blue Antibacterial Foam Dressings in the Effective Treatment of Wounds with Exposed Tendon and Bone in the High Risk Diabetic Foot. Society for Advanced Wound Care - Spring, San Diego, CA

Manufactured for:
AROA BIOSURGERY INC
340 Progress Drive, Manchester, CT 06042
1-860-337-7730
www.aroabio.com

AROA

Use of an Ovine Collagen with an Intact Extracellular Matrix (CECM) and negative pressure wound therapy (NPWT) as part of the wound management plan following limb salvage surgical intervention in high risk diabetic foot ulcers.

• **Adam Silverman, DPM**
Silverman Podiatry P.A., Baltimore, MD

Objective:

Demonstrate use of an Ovine Collagen with an Intact Extracellular Matrix (CECM)* and negative pressure wound therapy (NPWT) as part of the wound management plan following limb salvage surgical intervention in high risk diabetic foot ulcers.

Background:

Diabetes is a disease which is becoming more and more prevalent in our society.[1] As a result, more patients are developing complex lower extremity deformities which could lead to ulcerations that often progress to infection. As medical professionals, it is important that we realize the limb threatening diabetic foot ulceration or infection as early as possible so that we can provide patients with the urgent and aggressive wound care necessary for limb salvage. Patients who suffer a limb loss are more likely to suffer contralateral limb loss or even loss of life within the next few years.[2,3]

Case Descriptions:

These four cases involve high risk diabetic patients who were treated with surgical intervention. As a part of post-operative wound management, CECM and NPWT were utilized. CECM was applied to the wound bed, covered with a contact layer dressing,** and then a NPWT dressing was applied. Dressings were changed two to three times a week per instructions for use.

Conclusion:

In these cases, the use of CECM and NPWT as part of the wound management plan following limb salvage surgical intervention has assisted in the task of saving these limbs.

Case Study 1: Left Hallux Amputation

Patient: 65 year-old, Diabetes, neuropathy, smoker, chronic DFU on bilateral great toes with osteomyelitis

Past medical history:

- Bilateral amputation of Hallux, 1 week later the patient developed post-op infection on left foot and went back to OR for debridement and partial 1st metatarsal amputation

Initial wound
Wound management post-op:
Triple antibiotic solution packing, IV antibiotics, hyperbaric oxygen therapy (HBOT) was administered while in the hospital for a total of 5 treatments
Wound management:
Application of CECM, contact layer dressing, and NPWT. NPWT changed 3 times weekly but CECM only added weekly

Week 0
Wound management:
Start of CECM with NPWT
Wound measurement:
3.0 cm x 7.0 cm x 0.2 cm

Week 1
Wound description:
Can see some residual CECM in wound bed
Wound measurement:
2.6 cm x 6.8 cm x 0.1 cm

Week 3
Wound description:
Beefy red granulation tissue; epithelialization starting on perimeter of wound
Wound measurement:
2.1 cm x 7.5 cm x 0.1 cm

Week 6
Wound management:
Discontinued NPWT. Continued using CECM and gentian violet and methylene blue (GVMB) polyurethane (PU) antibacterial foam***
Wound measurement:
0.7 cm x 5.0 cm x 0.1 cm

Week 16
Wound measurement:
Wound closure

Case Study 2: Diabetic Foot Ulcer- Wet Gangrene

Patient: 70 year-old female

Past medical history:

- Diabetes, peripheral neuropathy, peripheral arterial disease, hypertension, end-stage renal disease and on hemodialysis

Initial wound
Wound management:
Patient presented to the clinic with wet gangrene on the right foot

Surgery:
Incision and drainage, partial 1st and 2nd ray amputations
Wound management post-op:
Triple antibiotic treatment, angioplasty 3rd post-op day, HBOT 5th day post-op, NPWT 12th day post-op, went to rehab 14th day post-op

Week 0
Wound management:
Start of CECM and NPWT (wound is 3 weeks old)
Wound measurement:
3.7 cm x 15.9 cm x 1.8 cm

Week 5
Wound description:
CECM can be seen in wound bed
Wound measurement:
1.3 cm x 10.5 cm x 0.2 cm

Week 8
Wound management:
NPWT discontinued, EDT, contact layer and compression wrap
Wound measurement:
1.1 cm x 10.3 cm x 0.2 cm

Week 16
Wound measurement:
Proximal 0.5 cm x 2.2 cm x 0.1 cm
Distal 0.4 cm x 0.5 cm x 0.1 cm

Week 24
Wound measurement:
Wound closure

Case Study 3: Right Toe Gangrene and Abscess

Patient: 63 year-old female, admitted medical center with right 2nd toe gangrene and abscess

Past medical history:

- Diabetes, neuropathy, peripheral arterial disease, coronary artery disease, and underwent partial right 2nd ray amputation (below)

Initial wound
Wound management post-op:
Antiseptic packing daily and oral antibiotics
Wound measurement:
2.0 cm x 1.0 cm x 3.0 cm

5 days Post-op
Wound description:
Granulating surgical wound with moderate drainage and macerated edges. Tendon exposed without exposed bone. The sutures are intact proximally and distally from amputation with no pain or signs of infection associated
Wound management:
Continue to pack would with antiseptic dressing, oral antibiotics and initiated HBOT
Wound measurement:
2.4 cm x 0.8 cm x 3.5 cm

Week 2-3
Wound description:
NPWT-only initiated at week 2 - application of CECM, contact layer dressing, and NPWT initialted week 3. NPWT changed 2 times weekly but CECM only added weekly
Wound measurement:
1.6 cm x 0.6 cm x 2.6 cm

Week 4
Wound description:
Increased granulation tissue, no tendon exposed, no pain or signs of infection, less drainage and no maceration
Wound measurement:
1.6 cm x 0.6 cm x 2.1 cm

Week 7
Wound measurement:
1.1 cm x 0.5 cm x 0.5 cm

Week 10
Wound description:
NPWT Discontinued. CECM, contact layer dressing, and multi-layer compression wrap initiated
Wound measurement:
1.0 cm x 0.4 cm x 0.2 cm

Week 13
Wound measurement:
0.1 cm x 0.1 cm x 0.1 cm

Week 18
5 weeks after wound closure

Case Study 4: Non-healing surgical wound after left partial 4th and 5th ray resection

Patient: 50 year-old female presented to wound care center after partial left 4th and 5th ray resections at another facility 3 weeks prior

Past medical history:

- Diabetes, neuropathy, peripheral arterial disease, heavy smoker

Initial wound
Previous wound management:
Patient arrived to wound center with a NPWT device in place and on oral antibiotics. NPWT was continued and changed 3 times per week after wound debridement
Wound measurement:
4.5 cm x 2.2 cm x 3.6 cm

Week 0
Wound management:
Application of CECM, contact layer dressing, and NPWT. NPWT changed 2 times weekly but CECM only added weekly
Wound measurement:
4.2 cm x 0.7 cm x 2.0 cm

Week 1
Wound measurement:
4.2 cm x 0.7 cm x 1.1 cm

Week 2
Wound management:
NPWT discontinued. CECM, contact layer dressing, and multi-layer compression wrap initiated
Wound measurement:
4.2 cm x 0.5 cm x 1.5 cm

Week 5
Wound measurement:
2.1 cm x 0.3 cm x 1.0 cm

Week 7
Wound measurement:
0.6 cm x 0.3 cm x 0.5 cm

Week 10
Wound management:
Discontinued CECM. Continued contact layer with compressin wrap
Wound measurement:
0.3 cm x 0.2 cm x 0.3 cm

Week 11
Wound measurement:
Wound closure

REFERENCES

1. United States, Department of Health and Human Services, Center for Disease Control and Prevention. (2011). National Diabetes Fact Sheet: National Estimates and General Information on Diabetes and Prediabetes in United States, 2011.
2. Reiber, G. E., Boyko, E. J., & Smith, D. G. (1995). Lower extremity foot ulcers and amputations in diabetes. Diabetes in America, 2, 409-427.
3. Larson, J., Agardh, C., Apelqvist, J., & Stenstrom, A. (1998). Long term prognosis after healed amputation in patients with Diabetes [Abstract]. Clinical Orthopaedics and Related Research, 350, 149-58.

* Endoform dermal template, Distributed by Hollister Incorporated.
** Restore contact layer FLEX, Distributed by Hollister Incorporated.
***Hydrofera Blue Ready foam, Distributed by Hollister Incorporated.

Financial Disclosure: The author received an honorarium from Hollister Incorporated.

Appulse

Silverman, A. (2017). Use of an Ovine Collagen with an Intact Extracellular Matrix (CECM) and negative pressure wound therapy (NPWT) as part of the wound management plan following limb salvage surgical intervention in high risk diabetic foot ulcers. Symposium on Advanced Wound Care - Spring, San Diego, CA

Manufactured for:
AROA BIOSURGERY INC
340 Progress Drive, Manchester, CT 06042
1-860-337-7730
www.aroabio.com

AROA

The use of an ovine collagen extracellular matrix dressing in conjunction with negative pressure wound therapy in the management of chronic diabetic foot ulcers.

• Gregory Vidovic, DPM, Resident • Paul Sykes, DPM, Director

University General Hospital Podiatric Surgery Residency, Houston, TX

Introduction:

The use of negative pressure wound therapy dressings (NPWT) on acute and chronic foot wounds is not only well established, it has become a modern paradigm in the treatment of difficult-to-treat, pervasive wounds. The role of NPWT in promoting healing is based on a compendium of effects included induction of granulation tissue, removal of exudates, decreasing bioburden and maintaining a hydrated healing environment.[5,6] Additionally, the application of a collagen dressing over chronic wounds has shown an overall decrease in wound surface in a case series of diabetic foot ulcers.[6] A class of several zinc-containing serine proteases including interstitial collagenases, gelatinases, and stromelysins collectively are known as the matrix metalloproteases (MMPs). MMP levels have been shown to be markedly elevated in chronic wounds among a plethora of other pathologic conditions. Here we present ten cases where NPWT was combined in conjunction with ovine collagen extracellular matrix dressing (CECM)* with an overall difference in time to wound closure compared to a retrospective control group in which this dual therapy was not used.

Materials and Methods:

A prospective case-control study was initiated after approval from the institutional review board. Patient selection and enrollment was non-randomized and continuous until the treatment group of ten patients was filled, with cases of NPWT paired with CECM. The control group data was constructed utilizing a retrospective analysis of the last ten patients previously treated with NPWT alone. The goal of the study was to evaluate and compare the overall time to wound closure of both groups.

Results:

The results demonstrated in chronic diabetic foot ulceration an average time to closure of 5.5 weeks in the treatment group using the CECM dressing and 7 weeks in the control group. This shows a mean difference of 10 days in time to wound closure when CECM as added to the regimen with NPWT. There were no adverse events reported.

Conclusion:

In this case series, when compared to NPWT alone, the addition of CECM to NPWT has shown a difference in time to wound closure in instances of long-standing diabetic foot ulcers.

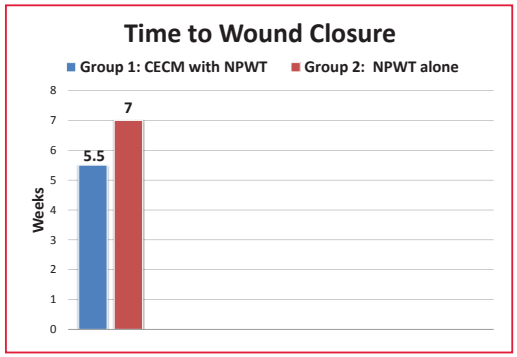

REFERENCES

1. American Diabetes Association. Standards of Medical Care in Diabetes - 2015. Diabetes Care; 38 (suppl 1): S1–S2. doi: 10.2337/dc15-S001
2. Leaper D, Assadian O, Edmiston CE. Approach to Chronic Wound Infections. Br J Dermatol. 2015 Epub Mar 15. doi: 10.1111/bjd.13677
3. Imirzalioglu C, Sethi S, Schneider C, Hain T, Chakraborty T, Mayser P, Domann E. Distinct polymicrobal populations in a chronic foot ulcer with implications for diagnostic and anti-infective therapy. BMC Res Notes. 2014 Mar 29;7:196. doi: 10.1186/1756-0500-7-196
4. O'Meara S, Al-Kurdi D, Ologun Y, Ovington LG, Martyn-St James M, Richardson R. Antibiotics and antiseptics for venous leg ulcers.Cochrane Database Syst Rev. 2013 Dec 23; 12:CD003557. Epub 2013 Dec 23.
5. Hasan MY, Teo R, Nather A. Negative-pressure wound therapy for management of diabetic foot wounds: a review of the mechanism of action, clinical applications, and recent developments. Diabetic Foot Ankle. 2015 Jul 1;6:27618.
6. Haycocks S, Chadwick P, Cutting KF. Collagen matrix wound dressings and the treatment of DFUs. J Wound Care. 2013 Jul;22(7):369-70, 372-5.

* Endoform dermal template, Distributed by Hollister Incorporated.

Case Study 1

Diabetic foot 3 weeks status post debridement for infection of left foot

Past medical history:

- Diabetes mellitus, hypertension, obesity, chronic kidney disease-Stage 3

Wound history:

- 3 weeks status post excisional debridement of infected dorsal medial foot wound that began as hallux ulceration and tunneled into the medial mid-foot along the first ray

Previous treatment:

- Sharp debridement, wet to dry dressings, double antibiotic ointment, hydrogel, silver alginate dressing

Current treatment:

- Weekly debridement with application of CECM and NPWT

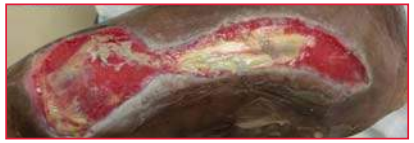

Week 0

Application of CECM dressing

Application of NPWT over CECM

Week 6

Case Study 2

Right diabetic foot ulcer

Past medical history:

- Diabetes mellitus, hypertension, obesity, hypothyroidism, fibromyalgia, Charcot neuroarthropathy

Wound history:

- 3 month history of chronic, recurrent plantar ulcer at greater tarsus fault secondary to Charcot collapse

Previous treatment:

- Curettage, wet to dry dressing, silver foam dressing, medical grade honey products, and off-loading boot

Current treatment:

- Weekly debridement with application of CECM and NPWT

Week 0

Application of CECM prior to NPWT

Week 7

Appulse

Vidovic, G. and P. Sykes (2016). The use of an ovine collagen extracellular matrix dressing in conjunction with negative pressure wound therapy in the management of chronic diabetic foot ulcers. Symposium on Advanced Wound Care - Fall, Los Vegas, NA

Manufactured for:

AROA BIOSURGERY
340 Progress Drive,
Manchester, CT 06042
1-860-337-7730

www.aroabio.com

AROA

As Presented at
Diabetic Limb Salvage Conference
October 10-12, 2013, Washington, DC

Clinical Symposium on Advances in Skin & Wound Care
October 24 – 27, 2013, Orlando, FL

Innovative Dressing Option: Use of a collagen dermal template with extracellular matrix (ECM)* in the management of lower extremity wounds

Kathy Wright, RN, CWOCN-AP, ACHRN,
Debby Hastings, RN,
Wendy Dukes, RN,
Dr. Khalil Gorgui, M.D. Nanticoke Wound Care and Hyperbaric Center

Introduction:

With the growing arsenal of advanced wound healing products, clinicians are challenged to select the best treatment option. Chronic wounds often present with high levels of a variety of matrix metalloproteinases (MMPs) which has been shown to result in delayed wound healing.[1,3] In excess, these proteases degrade the viable structures, including the extracellular matrix. This may result in delays in the use of optimal wound therapies which may extend the time to heal and may contribute to the development of further complications. One purpose of using of a collagen dermal template with extracellular matrix (ECM)* is to reduce the activity of a broad spectrum of MMPs and provide an extracellular matrix to help support the structure of the wound.[2]

Method:

Patients presented at an outpatient wound healing center with lower extremity wounds consisting of a variety of etiologies and had failed to progress over a period of months, despite utilization of a number of advanced topical treatments. Use of a collagen dermal template with EMC* was initiated. The collagen dermal template with ECM* was applied by treating physician at the wound healing center as deemed necessary. Due to socio-economic circumstances, the patients' return-to-clinic visits were sporadic. Therefore the collagen dermal template with ECM* application was restricted by the patients' ability to return to the wound healing center. Home care services were necessary in between clinic visits. Wounds were assessed and documented on a weekly basis for measurement of size, pain, progression to healing, and granulating wound base.

Outcome:

Clinicians observed consistent progress toward wound closure with the use of the collagen dermal template with ECM* based on an increase in granulation tissue formation in the wound bed as well as reductions in wound size through wound measurement tracking. Patients also reported a reduction in pain.

Conclusion:

Collagen dermal template with ECM* dressings are a valuable addition to the advanced wound product arsenal. In this case series, the chronic wounds exhibiting delayed wound healing advanced to wound closure while utilizing this treatment modality. The use of this option of a collagen dermal template with ECM* may have helped optimize the wound healing environment of lower extremity wounds consisting of a variety of etiologies. When considering the chronic wound environment, this modality may be considered as a first choice dressing for the progression toward healing the chronic wounds we treat.

Appulse

AROA

Rx **Caution:** Federal (USA) law restricts this device for sale by or on the order of a physician or licensed healthcare professional. Refer to Instruction for Use for contraindications, warnings, precautions and possible complications.

Manufactured for:
AROA BIOSURGERY INC
340 Progress Drive, Manchester, CT 06042
1-860-337-7730

www.aroabio.com

Case Study 1 - Right dorsal foot wound

42-year-old who presented to the wound clinic with an open wound of two months duration to the right dorsal foot as a result of a full thickness burn.

- Past medical history includes:
  Peripheral Arterial Disease (PAD), Type II Diabetes Mellitus with sensory neuropathy, and left trans-metatarsal amputation.
- Previous wound care treatment:
  Split-thickness skin graft, topical treatment included silver foam dressing, and honey hydrocolloid dressing.

Day 1: Onset of Care
Wound Dimensions: 3.0 cm X 1.5 cm X 0.3 cm

Wound description-treatment:
Wound bed dark red with serous drainage, 30% slough, no pain, or odors were noted. Wound margins macerated. Cleansed wound with normal saline solution, applied collagen dermal template with ECM*, and a border foam dressing to secure in place on initial visit.

Day 12: Wound after first collagen dermal template with ECM* application
Wound Dimensions: 2.2 cm X 0.9 cm X 0.2 cm

Wound description-treatment:
Wound bed is red and pink with healing edges. Dimensions decreased with a decrease noted in serous fluid drainage. Cleansed wound with normal saline solution, applied collagen dermal template with ECM,* and a border foam dressing to cover.

Day 22: Wound after 2 collagen dermal template with ECM* applications
Wound Dimensions: 1.6 cm X 0.7 cm X 0.1 cm

Wound description-treatment:
Wound bed progressed to 90% granulation tissue. Minimal serous fluid noted. Cleansed wound with normal saline solution, applied collagen dermal template with ECM,* and a border foam dressing to cover.

Day 29: Wound after 3 collagen dermal template with ECM* applications
Wound Dimensions: 0.5 cm X 0.2 cm X 0.1 cm

Wound description-treatment:
Wound bed progressed to further granulation with healed pink tissue noted to 95% with minimal serous fluid drainage. Cleansed wound with normal saline solution, applied collagen dermal template with ECM,* and a border foam dressing to cover.

Day 43: Wound after 4 collagen dermal template with ECM* applications



Wound Healed

Case Study 2 - Left heel ulcer

65-year-old resident of long-term care facility presents with a one month old ulcer to the left heel.

- Past medical history includes:
  Peripheral Vascular Disease (PVD), right below knee amputation, Coronary Artery Disease (CAD), Coronary bypass graft, and hypertension (HTN).
- Previous wound care treatment:
  Wound previously treated with silver hydrogel and other collagen dressings.

Day 1: Wound prior to first collagen dermal template with ECM* application.
Wound Dimensions: 3.0 cm X 1.2 cm X 0.2 cm

Wound description-treatment:
Scant amount of clear sero-sanguineous drainage with no odor noted. Patient insensate with wound pain rated as a zero. Wound bed had 50% yellow slough, 50% pink granulation tissue, and no sinus tract or undermining noted. Cleansed wound with normal saline solution, applied collagen dermal template with ECM*, and a border foam dressing to cover.

Day 9: Wound after 9 days of initial collagen dermal template with ECM* application.
Wound Dimensions: 0.7 cm X 0.4 cm X 0.1 cm

Wound description-treatment:
Minimal amount of clear sero-sanguineous drainage with no odor noted. Patient insensate with wound pain rated as a zero. Wound bed had 25% yellow slough, 75% pink granulation tissue, and no sinus tract or undermining noted. Wound significantly reduced from previous dressing change. Cleansed wound with normal saline solution, collagen dermal template with ECM*, and a border foam dressing to cover.

Day 23: Wound after 2 collagen dermal template with ECM* applications.
Wound Dimensions: 0.2 cm X 0.2 cm X 0.1 cm

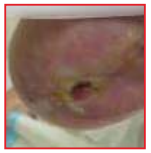

Wound description-treatment:
Minimal amount of clear sero-sanguineous drainage with no odor noted. Patient insensate with wound pain rated as a zero. Wound bed with pink granulation tissue and no sinus tract or undermining noted. Wound significantly reduced from previous dressing change. Cleansed wound with normal saline solution, applied collagen dermal template with ECM*, and a border foam dressing to cover.

Day 44: Wound after 3 collagen dermal template with ECM* applications.
Wound Dimensions: 0.2 cm X 0.2 cm X 0.1 cm

Wound description-treatment:
Minimal amount of clear sero-sanguineous drainage with no odor noted. Patient insensate with wound pain rated as a zero. Wound bed with pink granulation tissue and no sinus tract or undermining noted. Wound significantly reduced from previous dressing change. Cleansed wound with normal saline solution, applied collagen dermal template with ECM,* with border foam dressing to cover.

Case Study 3 - Left medial ankle wound

82-year-old who presented to the wound clinic with a 6-month-old, non-healing wound to the left medial ankle.

- Past medical history includes:
  Type II Diabetes Mellitus, hypertension, venous insufficiency, and gout.
- Previous wound care treatment: Various silver foam dressings, honey hydrocolloid dressings, and multilayer compression wraps.
- Diagnostics performed at initial visit: Ankle-Brachial Indices (ABI) with arterial dopplers of bilateral lower extremities were completed with normal limits to extremity noted. Venous dopplers reflected mild greater saphenous reflux on left lower extremity.

Day 1: Wound prior to first collagen dermal template with ECM* application
Wound Dimensions: 2.0 cm X 0.8 cm X 0.1 cm

Wound description-treatment:
Minimal amount of clear sero-sanguineous drainage with no odor, no complaint of pain, or signs of infection noted. Wound bed had 10% pink granulation tissue with 75% brown slough upon assessment. Cleansed wound with normal saline solution, applied collagen dermal template with ECM*, foam dressing, and multilayer compression wrap applied.

Day 14: Wound after first collagen dermal template with ECM* application
Wound Dimensions: 1.4 cm X 0.6 cm X 0.1 cm

Wound description-treatment: Minimal amount of clear sero-sanguineous drainage with no odor noted. Wound bed with 100% pink granulation tissue noted. Wound edges assessed for sinus tract and undermining with no sinus tract or undermining noted. Cleansed with normal saline solution, applied collagen dermal template with ECM*, foam dressing, and multilayer compression wrap applied.

Day 21: Wound healed

REFERENCES

1. Gibson, D., Cullen, B., Legerstee, R., Harding, K.G., & Schultz, G. (2009). MMPs made easy. Wounds International Journal, 1(1), 38-43..
2. Negron, S., Lun, S., May, B., & May, C.H. (2012). Ovine forestomach matrix biomaterial is a broad spectrum inhibitor of matrix metalloproteinase's and neutrophil elastase. International Wound Journal. doi: 10.1111/j.1742-481X.2012.01106.x
3. Schultz, G.S., Ladwig, G., & Wysocki, A. (2005). Extracellular matrix: Review of its roles in acute and chronic wounds. Journal of World Wide Wounds.

*Endoform® dermal template, AROA BIOSURGERY

Managing Diabetic Foot Ulcers Using a Three Pronged Approach: V.I.P.

• Jeffrey Roith, DPM
Overland Park, KS

Introduction:

Diabetic foot ulcers (DFUs) are a complication of diabetes that can be costly to treat, reduce quality of life, may lead to amputation, and even death.[1] An excess of matrix metalloproteinases (MMPs) and decreased tissue inhibitors of metalloproteinases (TIMPs) may contribute to diabetic ulcers not healing.[2] Vascular management (V), infection management and prevention (I), and pressure relief (P) are essential to DFU healing.[1] Total contact casting is the gold standard for DFU management. However, off-loading alone will fail to present optimal outcomes if vascular disease or infection is not appropriately managed.[1] Utilizing a total contact cast (TCC) system comprised of a clamshell cast with off-loading footplate* that includes products needed to address the V.I.P.s can be helpful to manage DFUs.

Method:

Three DFU patient's wounds were managed using ovine collagen with an intact extra cellular matrix (CECM) ** as a primary dressing and methylene blue and gentian violet (MB/GV) polyurethane (PU) antibacterial foam*** dressing to help manage bioburden as a secondary dressing and placed in a TCC system. The off-loading system provided a multilayer footplate that the clinician custom cuts for each patient. The unique clamshell cast provided a 7-layer fiberglass structure to accommodate different sized patients while maintaining durability. All patients were placed in a CAM boot and were able to ambulate immediately after TCC system comprised of a clamshell cast with off-loading footplate was applied. Patients returned to the clinician's office weekly for wound dressing and TCC system changes.

Results:

All three patients had wound closure within 12 weeks and without infection. The TCC system comprised of a clamshell cast with off-loading footplate provided the needed solution to provide V.I.P. treatment to these DFU patients.

Case Study 1

Patient: 56 year-old.

Past medical history:

- Hypertension, chronic obstructive pulmonary disease, diabetes, peripheral vascular disease, peripheral neuropathy, Charcot foot. Recurrent wound for the last 2 years. Current wound is six months old.

Previous wound management:

- Cellular tissue product, collagen with oxidized regenerated cellulose, debridement, and foam dressings were used for 21 weeks.
- CECM, GV/MB antibacterial PVA foam used with an offloading diabetic shoe for 3 weeks. Despite advanced wound dressings and diabetic shoe, wound did not progress.

Wound management:

- CECM covered with GV/MB PU antibacterial foam were applied to the wound and secured with tape.
- Applied with TCC system comprised of a clamshell cast with offloading footplate.
- Changed weekly for a total of 8 applications.

Week 0
Wound measurement:
0.8 cm x 0.7 cm x 0.7 cm

Week 1
Wound measurement:
0.6 cm x 0.5 cm x 0.2 cm

Week 5
Wound measurement:
Wound size decreased with healthy granulating tissues

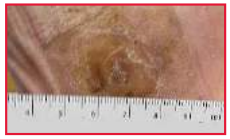

Week 8
Wound measurement:
100% re-epithelialized

Case Study 2

Patient: 48 year-old.

Past medical history:

- Diabetes, CVA, Charcot deformity.

Age of wound:

- 3 weeks.

Previous wound management:

- Antibiotic ointment and off-loading with post-operative shoe.

Wound management:

- CECM covered with GV/MB PU antibacterial foam were applied to the wound and secured with tape.
- Applied TCC system comprised of a clamshell cast with off-loading footplate

Week 0
Wound measurement: Post-debridement
2.4 cm x 1.4 cm x 0.3 cm

Week 1
Wound measurement: Post-debridement
1.0 cm x 0.8 cm x 0.2 cm

Week 2
Wound measurement: Pre-debridement
0.5cm x 0.4cm x 0.2cm
No debridement performed

Week 3
Wound measurement: Post-debridement
1.0cm x 0.8cm x 0.3cm

Week 4
Wound measurement: Post-debridement
0.7cm x 0.6cm x 0.1cm

Week 5
Wound measurement:
Wound Closure

Case Study 3

Patient: 69 year-old who was initially seen prior for idiopathic peripheral neuropathy and a bilateral charcot deformity with a wound on the plantar aspect of the right foot.

Past medical history:

- Hypertension, Dyslipidemia, Coronary artery bypass graft x 3, Atrial fibrillation.

Previous wound management:

- Patient was treated conservatively for 8 weeks and refused casting until the wound failed to respond and close.

Wound management:

- CECM covered with GV/MB PU antibacterial foam were applied to the wound and secured with tape.
- Applied TCC system comprised of a clamshell cast with off-loading footplate
- Wound closure was achieved in 6 weeks after adding these to the overall wound management plan.

Week 0
Wound measurement:
1.0 cm x 1.4 cm x 0.3 cm

Week 2
Wound measurement:
0.8 cm x 0.5 cm x 0.3 cm

Week 5
Wound measurement:
Wound Closure

Conclusion:

Without proper pressure relief, successful healing will be unlikely even when using advanced therapeutics.[1] In these cases, the addition of the TCC system comprised of a clamshell cast with offloading footplate, which includes CECM and GV/MB PU antibacterial foam dressings, helped the wounds get back on a healing trajectory.

REFERENCES

1. Snyder, RJ, et al. The Management of Diabetic Foot Ulcers Through Optimal Offloading Building Consensus Guidelines and Practical Recommendations to Improve Outcomes; Journal of American Podiatric Medical Association. 2014; 104(6): 555-567.
2. Lobmann, R., et al, (2002). Expression of matrix-metalloproteinases and their inhibitors in the wounds of diabetic and non-diabetic patients. Diabetologia, (45), 1011–1016-1011–1016. doi:DOI 10.1007/s00125-002-0868-8
3. Hollister, Incorporated. (n.d.). Endoform dermal template brochure

* FastCast OLS, Distributed by Hollister Incorporated.
** Endoform dermal template, Distributed by Hollister Incorporated.
*** Hydrofera Blue Ready foam, Distribute by Hollister Incorporated.

Financial Disclosure: J. Roith received an honorarium from Hollister Incorporated.

Appulse

Roith, J. (2016). Managing Diabetic Foot Ulcers Using a Three Pronged Approach: V.I.P. Symposium for Advanced Wound Care - Fall, Las Vegas, NA

Manufactured for:
AROA BIOSURGERY INC
340 Progress Drive, Manchester, CT 06042
1-860-337-7730
www.aroabio.com

AROA

Use of ovine collagen extracellular matrix (CECM)* dressing and gentian violet and methylene blue (GV/MB) antibacterial foam** dressing in the management of diabetic foot ulcers

• **Dr. Igor Zilberman, DPM, Dr. Nooshin Zolfaghari, DPM, CWS, MPH,** South Florida Lower Extremity Center Hollywood, FL

INTRODUCTION:

Diabetic foot ulcers (DFU) are estimated to affect ~15% of all diabetic individuals during their lifetime.[1] The management and treatment of DFU's can be costly and complex. In 2008, the mean reimbursement for all Medicare related services for DFU's was $35,100.[2] DFU's also have a negative effect in the quality of life on diabetic patients as a result of decreased mobility.[3] Early intervention is important to prevent further complications and improve quality of life of patients with DFU's. Chronic wounds represent a failure in the normally ordered sequence of wound healing. Changes in local pH, temperature, and amounts of chemical reactants are all factors influencing wound healing. The three main components of local wound management include: debridement, infection/inflammation, and moisture balance. Bioburden, or critical bacterial colonization, leads to persistently high levels of matrix metalloproteinases (MMP) being released from inflammatory cells that digest the normal collagen scaffold in the base of a healing wound. Using advanced wound care products may assist to achieve wound healing in a timely manner.[4]

OBJECTIVE:

To describe the use of CECM, and in combination with gentian violet and methylene blue (GV/MB) antibacterial foam,** to manage MMPs and bioburden in DFU.

METHODS AND MATERIALS:

Patients were selected with wounds of diabetic origins. The CECM and GV/MB antibacterial dressings were changed according to product instructions for use. Assessments and measurements were performed by the clinician weekly.

CONCLUSION:

The use of the dressings in this case series were helpful in the management of these complex wounds. Both the CECM and GV/MB antibacterial foam dressings may have been instrumental in MMP and bioburden reduction with complete resolution of wounds without complication. Overall patient satisfaction and compliance were also observed by the clinician.

Case Study 1 - Diabetic Foot Ulcer - Right Plantar 5th metatarsal

Patient: 70 year-old male with one week old diabetic foot ulcer.

Past medical history:

- Diabetes with neuropathy, hypertension.

Previous treatment:

- None.

Wound treatment:

- Sharp debridement
- CECM, non-adherent contact layer, *** GV/MB antibacterial foam dressing secured with rolled gauze. Dressing changed weekly.
- Post-op shoe with accommodative padding

Initial wound measurement:
1.2 cm x 1.4 cm x 0.4 cm
Wound Description:
Post debridement, Bone palpable

Week 9 Wound measurement:
0.2 cm x 0.2 cm x 0.2 cm

Week 7 Wound measurement:
0.5 cm x 0.4 cm x 0.3 cm

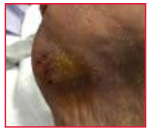

Week 10
Wound healed

Case Study 2 - Diabetic Ulcer-Achilles

Patient: 70-year-old male with 8-month-old diabetic ulcer over Achilles

Past medical history:

- Uncontrolled diabetes, neuropathy, peripheral vascular disease, > 50 years of tobacco use.
- Revascularizations with stents to left leg and angiography x 2.

Previous treatment:

- Failed Cellular tissue based wound dressing for 21 days

Wound treatment:

- Application of hydrogel and CECM covered with non-adherent contact layer, silver foam, and secured with roll gauze. Dressings changed weekly.

Initial wound measurement:
8.0 cm x 5.0 cm x 0.4 cm
Wound Description:
80% Granulation tissue, 20% fibrous tissue with moderate drainage

Week 20 Wound measurement:
1.5 cm x 0.5 cm x 0.3 cm

Week 9 Wound measurement:
7.0 cm x 1.5 cm x 0.4 cm
Wound Description:
90% granulation to 10% fibrous tissue

Week 24 Wound measurement:
1.0 cm x 1.2 cm x 0.3 cm

Week 14 Wound measurement:
5.0 cm x 1.5 cm x 0.3 cm

Week 31
Wound healed

Case Study 3 - Diabetic foot ulcer: Right Dorsal Foot

Patient: 59-year-old male presented to emergency room with acute necrotizing gangrene with abscess of right dorsal foot with osteomyelitis

Past medical history:

- Hypertension, uncontrolled diabetes

Previous treatment:

- 2nd and 3rd Ray resection with incision and drainage of abscess.
- Systemic antibiotic for 14 days.
- Post ray resection, began 1 week of Negative pressure wound therapy (NPWT) followed by an Amniotic stem cell graft for 2 weeks.
- At week 4, CECM was applied one time for 1 week and discontinued due to copious amount of drainage.

Wound treatment:

- At week 5, the use of GV/MB antibacterial polyvinyl alcohol (PVA) foam,**** 4x4 sterile gauze, secured in place with rolled gauze and elastic bandage. Dressings changed 3 times a week for one week. After one week, frequency was changed to daily due to copious amount of drainage.
  At week 20, drainage decreased. GV/MB antibacterial PVA foam was discontinued. Wound treatment changed to hydrogel, CECM, covered with non-adherent contact layer , 4x4 sterile gauze, secured with roll gauze and elastic bandage. Dressing changes were done once a week.

Initial wound measurement:
14.0 cm x 5.0 cm x 0.8 cm
Wound Description:
Clean red tissues with heavy serosanguinous drainage with tendon exposed

Week 17 Wound measurement:
6.3 cm x 0.8 cm x 0.3 cm

Week 5 Wound measurement:
13.0 cm x 7.5 cm x 0.8 cm
Wound Description:
Red granulating tissue with tendon visible

Week 19 Wound measurement:
6.0 cm x 0.5 cm x 0.3 cm

Week 9 Wound measurement:
8.5 cm x 2.0 cm x 0.3 cm
Wound Description:
Granulating tissues with epithelialization on wound edges

Week 21
Wound healed

Case Study 4 -Diabetic Foot Ulcer- Left Lateral Foot

Patient: 55-year-old female presented to emergency room with elevated white count, febrile with acute necrotizing gangrene to left lateral foot with osteomyelitis.

Past medical history:

- Uncontrolled diabetes, neuropathy

Previous treatment:

- 4th and 5th ray resection with incision and drainage of abscess.
- Systemic antibiotic for 14 days.
- Negative pressure wound therapy (NPWT) for one week post-surgery.
- Cellular tissue based wound dressing was applied for 21 days

Wound treatment:

- Application of hydrogel and CECM, covered by a non-adherent contact layer and GV/MB antibacterial PVA foam, and secured with roll gauze. Based on clinical preference, dressing changed weekly.

Initial wound measurement:
9.0 cm x 3.5 cm x 0.3 cm

Week 11 Wound measurement:
1.0 cm x 0.5 cm x 0.2 cm

Week 2 Wound measurement:
8.0 cm x 3.0 cm x 0.3 cm

Week 13
Wound healed

Week 5 Wound measurements:
1.0 cm x 0.5 cm x 0.2 cm
3.0 cm x 1.5 cm x 0.2 cm
Wound Description:
Wound separated into 2 wounds

REFERENCES:

1. Reiber, Gayle E., Edward J. Boyko, and Douglas G. Smith. "Lower Extremity Foot Ulcers and Amputations in Diabetes." *Diabetes in America 2* (1995): 409-27.
2. Margolis DJ, Malay DS, Hoffstad OJ, et al. Economic burden of diabetic foot ulcers and amputations. Diabetic Foot Ulcers. Data Points #3 (prepared by the University of Pennsylvania DEcIDE Center, under Contract No. HHSA290200500411). Rockville, MD: Agency for Healthcare Research and Quality. January 2011.AHRQ Publication No. 10(11)-EHC009-2-EF.
3. Goodridge, D., Trepman, E., & Embil, J. (2005). Health-related quality of life in Diabetic patients with foot ulcers: Literature Review. *Journal of WOCN, 32*(6), 368-377.
4. Sibbald, R., Ovington, L., & Goodman, L. (2014). Wound bed preparation 2014 update: Management of critical colonization with a gentian violet and methylene blue absorbent antibacterial dressing and elevated levels of matrix metalloproteases with an ovine collagen extracellular matrix dressing. *Advances in Skin and Wound Care: The International Journal of Prevention and Healing, 27*, 3 suppl 1, 1-6.

* Endoform dermal template, Distributed by Hollister Incorporated
** Hydrofera Blue Ready foam, Distributed by Hollister Incorporated
*** Restore Contact Layer FLEX, Hollister Incorporated
**** Hydrofera Blue classic foam, Distributed by Hollister Incorporated

Appulse

Zilberman, I. and N. Zolfaghari (2014). Use of ovine coll agen extracellular matrix (CECM) dressing and gentian violet and methylene blue (GV/MB) antimicrobial foam dressing in the management of diabetic foot ulcers. The Symposium on Advanced Wound Care - Fall. Las Vegas, NA

Manufactured for:
AROA BIOSURGERY INC
340 Progress Drive,
Manchester, CT 06042
1-860-337-7730
www.aroabio.com

AROA

Innovative solutions in the management of wounds with exposed tendons utilizing ovine collagen extracellular matrix and gentian violet and methylene blue antibacterial foams.

• **Dr. Igor Zilberman, DPM** • **Nooshin Zolfaghari DPM, CWS, MPH,** South Florida Lower Extremity Center, Hollywood, FL

INTRODUCTION:

Tendons are anatomical structures that connect muscle to bone. They are composed of parallel bundles of collagen fiber and often appear at striated white or cream yellow structures in wound beds.[1] Tendons are nourished by blood vessels and by diffusion of nutrients from synovial fluid.[2] Because nourishment is disrupted when the tendon is exposed, meticulous care must be provided to prevent infection and desiccation. Either of these two may result in loss of tendon viability.[3]

Tendons may be exposed in trauma wounds, stage IV pressure wounds, diabetic wounds, and contaminated or infected surgical wounds.[4] Chronic wounds represent a failure in the normal order and sequence of wound healing. Changes in local pH, temperature, and amounts of chemical reactants are all factors influencing wound healing.

The three main components of local wound management include debridement, infection/inflammation, and moisture balance. Bioburden, or critical bacterial colonization, leads to persistently high levels of matrix metalloproteinases (MMP) being released from inflammatory cells that digest the normal collagen scaffold in the base of a healing wound.[5] Addressing these key barriers to wound healing with use of advanced wound care products may assist to achieve tendon coverage and promote wound healing.

OBJECTIVE:

To describe the use of an ovine collagen with an intact ECM* (CECM) and gentian violet and methylene blue (GV/MB) polyurethane (PU) and/or polyvinyl alcohol (PVA) antibacterial foam**, *** in wounds with exposed tendons.

METHODS AND MATERIALS:

Patients were selected with wounds containing either partial or complete tendon exposure. The CECM dressings and GV/MB foams were changed according to product instructions. Assessments and measurements were performed by the clinician weekly.

CONCLUSION:

The use of the CECM dressing with GV/MB antibacterial foams in this case series were helpful in the management of these complex wounds. Complete tendon coverage and resolution of wounds were without complication.

Case Study 1 - Surgical wound- Right Dorsal Foot

Patient: 41 year-old male presented to emergency room with cellulitis, swelling and a blister on right hallux and metatarsal. Abscess was noted on the right lateral dorsal foot. MRI revealed osteomyelitis.

Past medical history:
- Hypertension, diabetes.

Wound history:
- First ray resection on right foot with debridement of abscess on right dorsal foot. IV antibiotics. Hospitalized for 1½ weeks.

Previous treatment:
- Negative pressure wound therapy (NPWT) alone during hospital stay. CECM, hydrogel, covered with non-adherent contact layer and NPWT for 5 weeks.

Treatment:
- NPWT discontinued. Treatment changed to CECM covered with MB/GV PVA antibacterial foam covered with dry gauze and secured with gauze wrap. Dressings changed every other day.

Week 0 Wound measurement: 9.8 cm x 7.0 cm x 0.5 cm
Wound Description: Granulating tissues with some non-viable tissues. Extensor tendon 3, 4 and 5 exposed.

Week 6 Wound measurement: 7.4 cm X 5.0 cm
Wound Description: Hyperganulating tissues. 20% of tendon exposed.

Week 2

Week 8 Wound measurement: 5.0 cm X 3.4 cm
Wound Description: 100% granulating wound bed with smooth flat wound edges. No tendons exposed.

Week 4 Wound measurement: 7.5 cm x 5.5 cm

Week 15
100% re-epithelialized.

Case Study 2 - Dehisced surgical wound - 2nd right toe

Patient: 59 year-old female presented to clinic with dehisced surgical incision on 2nd right toe osteomyelitis.

Past medical history:
- Hypertension, hepatitis C.

Wound history:
- Revision of hammertoe on right 2nd toe.

Previous treatment:
- N/A.

Treatment:
- Sutures removed. Applied CECM, hydrogel and covered with MB/GV antibacterial PU foam dressing. Dressings changed weekly.

Week 0 Wound measurement: 2.0 cm x 1.4 cm x 0.3 cm
Wound Description: Granulating tissues with extensor tendon exposed.

Week 7
Wound Description: 100% granulating tissues. Tendon covered.

Week 3 Wound measurement: 1.5 cm x 0.7 cm x 0.3 cm

Week 9
100% re-epithelialized.

Week 5 Wound measurement: 0.8 cm x 0.4 cm x 0.2 cm

Case Study 3 - Pressure Ulcer - Achilles

Patient: 80 year-old male living in a skilled nursing facility, bed bound with 3 month old pressure ulcer to the achilles.

Past medical history:
- Peripheral vascular disease, congestive heart failure.

Wound history:
- N/A

Previous treatment:
- Enzymatic debrider for 4 weeks to remove black eschar.

Treatment:
- Applied CECM, covered with MB/GV PU antibacterial foam, secured with gauze wrap. Dressings changed every other day.

Week 0 Wound measurement: 5.5 cm x 2.5 cm x 1.0 cm
Wound Description: Achilles tendon exposed.

Week 5 Wound measurement:
Proximal - 0.8 cm x 0.3 cm
Distal - 2.0 cm x 0.5 cm

Week 2 Wound measurement: 4.5 cm x 1.2 cm x 1.0 cm

Week 6
Re-epithelialized

Week 3 Wound measurement:
Wound split into 2.
Proximal - 1.0 cm x 1.0 cm x 0.2cm
Distal - 3.0 cm x 1.2 cm x 0.2 cm
Granulating tissues, tendon covered.

Case Study 4 - Diabetic Foot Ulcer – Left First Metatarsal

Patient: 51 year-old male with diabetic foot ulcer.

Past medical history:
- Diabetic with abscess on left first metatarsal.

Wound history:
- N/A

Previous treatment:
- Incision and drainage of abscess with debridement of necrotic tissues.
- Systemic antibiotic for 2 weeks.
- Wound dressings: Wet to dry dressings for 2 weeks.

Treatment:
- Applied CECM, covered with MB/GV PU antibacterial foam, secured with stretch gauze and elastic bandage. Dressings changed weekly.

Week 0 Wound measurement: 8.5 cm x 4.0 cm x 0.5 cm
Wound Description: 70% Red granulating tissues with 30% tendon exposed.

Week 4 Wound measurement: 8.0 cm x 3.0 cm x 0.2 cm
Wound Description: 100% red granulating tissues. Tendon completely covered with granulation tissues.

Week 1 Wound measurement: 8.5 cm x 3.5 cm x 0.5 cm
Wound Description: 80% red granulating tissues with 20% tendon exposed.

Week 8 Wound measurement: 4.6 cm x 3.0 cm x 0.2 cm
Wound Description: Wound continues to reduce in size.

Week 2 Wound measurement: 8.5 cm x 3.5 cm x 0.2 cm
Wound Description: Tendon continued to be covered with granulation tissue.

Week 10
Wound Description: Re-epithelialized

REFERENCES

1. Copstead LC, Banasik JL. Pathphysiology - Biological and Behavioral Perspectives, 2nd ed. Philadelphia, PA: W.B. Saunders;2000.
2. Grumble TE. Principles of Hand Surgery and Therapy. Philadelphia, PA: W.B. Saunders;2000.
3. Buchsolz RW, Heckman JD, Court-Brown CM (eds). Fractures in Adults, Vol. 1. Philadelphia, PA: Lipincott, Williams & Williams;2006.
4. Brotzman SB (ed). Clinical Orthopaedic Rehabilitation. St. Louis, MO: Mosby; 1996.
5. Sibbald, R., Ovington, L., & Goodman, L. (2014). Wound bed preparation 2014 update: Management of critical colonization with a gentian violet and methylene blue absorbent antibacterial dressing and elevated levels of matrix metalloproteases with an ovine collagen extracellular matrix dressing. Advances in Skin and Wound Care: The International Journal of Prevention and Healing, 27, 3 suppl 1, 1-6

* Endoform dermal template. Distributed by Hollister Incorporated.
** Hydrofera Blue Ready foam, Distribute by Hollister Incorporated.
*** Hydrofera Blue classic foam, Distributed by Hollister Incorporated.

Appulse

Zilberman, I. and N. Zolfaghari (2016). Innovative solutions in the management of wounds with expo sed tendons utilizing ovine collagen extracellular matrix and gentian violet and methylene blue antib acterial foams. Symposium on Advaanced Wound Care - Atlanta, GA

Manufactured for:

AROA BIOSURGERY
340 Progress Drive,
Manchester, CT 06042
1-860-337-7730

www.aroabio.com

AROA

endoform®

CASE STUDY 18 | Dorsal Diabetic Foot Ulcer

Patient: 57 year-old male with diabetic foot ulcer

Past medical history:

- Acute abscess with seropurulent exudate on the dorsal foot

Previous Treatment:

- Incision and drainage of the abscess
- Systemic antibiotics for 2 weeks
- Negative pressure wound therapy (NPWT) with cellular tissue based produ for 2 weeks
- CPT continued for another week post discontinuance of NPWT

Wound Treatment:

- Endoform dermal template, Restore contact layer FLEX,
- Hydrofera Blue classic foam, secured with stretch gauze.
- Unna boot applied. Dressings changed every 72 hours

One week post cellular tissue based product. CPT appears to be incorporating well.

Three weeks later, tendon is exposed. No signs of infection. CPT appears to not be incorporating well.

Week 0:

Endoform® dermal template added to treatment.

Endoform® dermal template applied over the remaining CPT, covered with Hydrofera Blue classic foam. Hydrofera Blue classic foam changed and **Endoform**® dermal template applied every 72 hours.

Week 4:

Wound decreased in size, wound bed has granulation tissue with tendon exposed. Wound edges are smooth and flattened with epithelial cells. Remnants of **Endoform**® dermal template (clear to light yellowish film) is observed in the wound bed on dressing change. **Endoform**® dermal template added to the wound and continued with same wound treatment.

Week 6:

Wound size continues to decrease. Red beefy granulation growing over the tendon.

Week 10:

Tendon completely covered and wound size significantly reduced.

Week 17:

Re-epithelialized.

Case provided by:

Eric Lullove, DPM CWS FACCWS, Medical Director, West Boca Center for Wound Healing, Boca Raton, Florida.

RX Only. Prior to use, be sure to read the entire Instructions for Use package insert supplied with the product.

For product questions, sampling needs, or detailed clinical questions concerning our products in the US, please call 1-860-337-7730

HCPCS are for reference only and subject to change.

Endoform® is a registered trademark of Aroa Biosurgery Limited.

Appulse

Endoform® **Dermal Template** is marketed in the USA by Appulse

AROA

Manufactured for:
AROA BIOSURGERY INC
340 Progress Drive, Manchester, CT 06042
1-860-337-7730
www.aroabio.com

endoform®

CASE STUDY 20 | Diabetic Foot Ulcer – Left First Metatarsal

Patient: 51 year-old male with diabetic foot ulcer

Past medical history:

- Diabetic with abscess on left first metatarsal

Previous Treatment:

- Incision and drainage of abscess with debridement of necrotic tissues
- Systemic antibiotic for 2 weeks
- Wound dressings: Wet to dry dressings for 2 weeks

Wound Treatment:

- Endoform dermal template, Hydrofera Blue Ready foam secured with stretch gauze and elastic bandage. Dressings changed weekly.

Week 0:
Wound measurements: 8.5 cm x 4.0 cm x 0.5 cm
Wound description: 70% Red granulating tissues with 30% tendon exposed

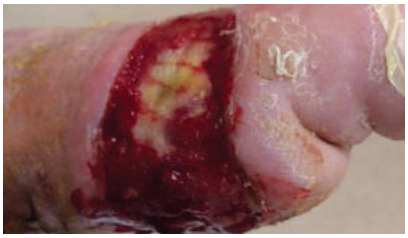

Week 1:
Wound measurements: 8.5 cm x 3.5 cm x 0.5 cm Wound description: 80% red granulating tissues with 20% tendon exposed

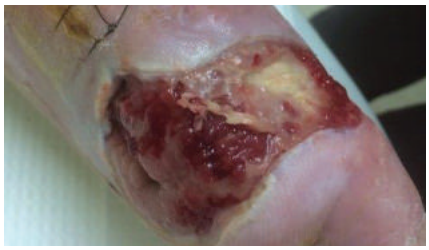

Week 2:
Wound measurements: 8.5 cm x 3.5 cm x 0.2 cm Wound description: Tendon continued to be covered with granulation tissue

Week 4:
Wound measurements: 8.0 cm x 3.0 cm x 0.2 cm Wound description: 100% red granulating tissues. Tendon completely covered with granulation tissues

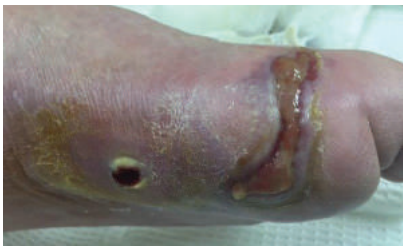

Week 8:
Wound measurements: 4.6 cm x 3.0 cm x 0.2 cm
Wound
description: Wound continues to reduce in size

Week 10: Wound description: Re-epithelialized

Case provided by:
Dr. Igor Zilberman DPM, South Florida Lower Extremity Center, 2699 Stirling Road, Hollywood, FL 33312.

RX Only. Prior to use, be sure to read the entire Instructions for Use package insert supplied with the product.

For product questions, sampling needs, or detailed clinical questions concerning our products in the US, please call 1-860-337-7730

HCPCS are for reference only and subject to change.

Appulse

Endoform® Dermal Template is marketed in the USA by Appulse

AROA

Manufactured for:
AROA BIOSURGERY INC
340 Progress Drive, Manchester, CT 06042

1-860-337-7730
www.aroabio.com