

Evaluating the Use of Hydrogel Sheet Dressings in Comprehensive Burn Wound Care

OSTOMY WOUND MANAGEMENT / VOLUME: 53

Issue Number: 3

author: Andrew Burd, MD, FRCSEd, FHKAM (Surgery)

Burn wound management is determined by the depth and site of the burn.¹ At the Prince of Wales Hospital, Shatin, Hong Kong, effective management strategies are based on a descriptive classification of the depth of burn injury (see Figure 1). Algorithms managing burns of specific wound depth^{1,2} have been developed based on the availability of local resources and expertise and depend on inhouse preparation of a range of biomaterials used in conjunction with selective commercially available dressings (see Figure 2).

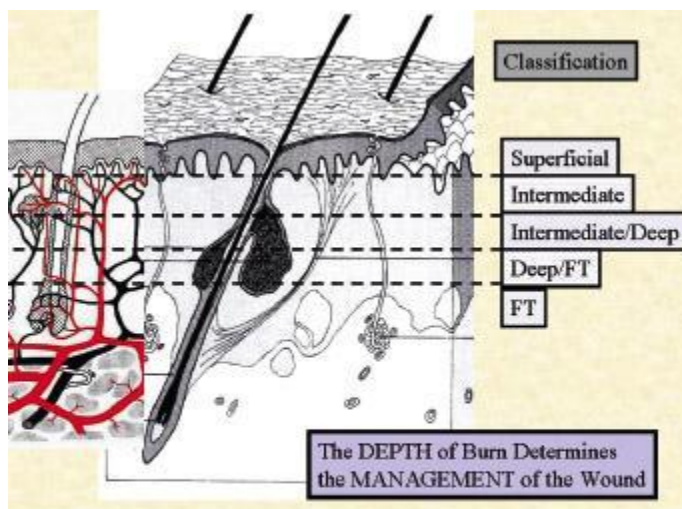


Figure 1. A pragmatic classification with depth determined by a combination of history, clinical examination, and examination under anesthesia where appropriate.

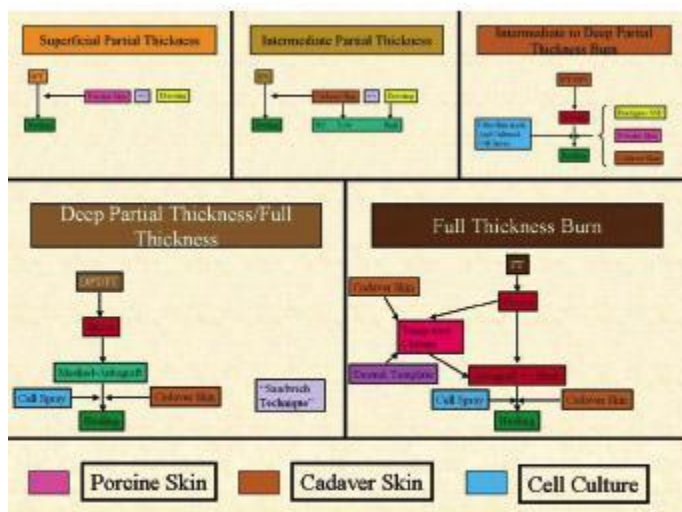


Figure 2. Management algorithms^{1,2} for hydrogel use.

TABLE 1
MANAGEMENT OF EXUDATIVE AND NON-EXUDATIVE WOUNDS

Superficial Partial-Thickness Wound with No Exudate

- Wound is cleansed with normal saline or chlorhexidine solution and hydrogel applied with overlap of 1cm to 2 cm. If multiple sheets are applied, they should be overlapped, not abutted
- Gauze dressing is applied over the hydrogel and held in place by either crepe bandages or adhesive tape. Note: The gauze dressing gauze will adhere to the hydrogel; the dressing needs careful inspection after 48 hours. If the gauze is dry, the dressing can be left for 5 to 7 days when the hydrogel has become a protective "crust" and the gauze can be removed. When the wound has re-epithelialized, the hydrogel lifts off and can be trimmed back or soaked off

Partial-Thickness Wound with Exudate

- These are generally slightly deeper burns. Method of hydrogel use is similar to the non-exudative burn; by 48 hours, the gauze dressing will contain exudate. The hydrogel and gauze can be replaced as often as necessary until the wound dries or a decision is made to surgically debride the wound

Ostomy Wound Management 2007;53(3):52-62

KEY POINTS

- The author of this clinical evaluation describes how unanticipated problems with the supply of biological dressings resulted in exploring the use of a hydrogel sheet to manage burn wounds and skin graft donor sites.
- The results of subsequent controlled clinical studies may confirm that hydrogel sheet dressings provide a safe and effective alternative to currently available biological and synthetic dressings for burn-related wounds.

This customized approach is necessary considering the vast array of wound dressings available.³ The local skin bank associated with the hospital is responsible for harvesting and processing porcine and cadaver skin. The biological material must be sent from the Hong Kong Special Administrative Region, China to Shenzhen in Mainland China. When customs regulations related to importing/exporting biological tissues changed, it became necessary to secure an affordable and effective temporary replacement for porcine and cadaver skin used in wound management algorithms. Primary considerations were cost, availability, and effectiveness. The range of skin substitutes available⁴ was considered, including Biobrane (Bertek Pharmaceuticals, Inc. Morgantown, WV). Biobrane has been described as efficacious in treating burns and scald injuries in children.⁵ Glycerolized cadaver skin from the Euroskin Bank also was considered because the hospital unit had used this previously during times of increased demand for biological dressings.⁶ Although these options would be cost-effective substitutes for locally supplied cadaver skin, they were too expensive as a replacement for porcine skin. In addition, the potential cytotoxicity of some of the silver-based burn and wound care materials (eg, laminates, foams, and fibers⁷) caused concern.

In the context of exploring new potential wound care dressings, the author had received a grant from the Hong Kong SAR government for laboratory and clinical studies of a hydrogel base combined with electrochemical modulation (Innovation and Technology Fund, the Government of the Hong Kong SAR to Prof. Andrew Burd, ITS/086/03).

Hydrogel Sheet Dressings

According to a published review,⁸ hydrogel wound dressings comprise a range of materials and include a permanent, three-dimensional network of hydrophilic polymers; water fills the space between the polymer chains. Hydrogel dressings are available as gels, sheets, and gels pre-applied to gauze. The amorphous gels are used for cavity wounds; sheet dressing and impregnated gauze can be applied to surface wounds.⁸ Their biomedical applications include wound care products, dental and ophthalmic materials, drug delivery systems, elements of implants, and tissue fillers.^{9,10} Purely synthetic hydrogels are frequently made from polyvinyl pyrrolidone, polyacrylamide, or polyethylene oxide. One of these basic constituents, polyacrylamide, has gained some recent notoriety because of its association with injectable hydrogel fillers and the theoretical possibility that the product can degrade to a neurotoxic and/or carcinogenic monomer.¹¹⁻¹³ The hydrogel used in the current evaluation contains polyvinyl pyrrolidone, polyethylene glycol, and agar. The sterile permanent hydrogel forms a transparent sheet 3 mm to 4 mm thick. Hydrogel is Conformité Européenne marked (European Conformity — CE) and cleared for marketing by the US Food and Drug Administration (FDA).

Several options regarding sheet hydrogels were (or have been) available. As reviewed by Eisenbud,⁸ a number of studies have compared amorphous hydrogels with other dressing strategies, particularly in the treatment of chronic wounds such as pressure ulcers.⁸ However, there is a paucity of reports on clinical trials regarding sheet hydrogel dressings and burn care. Product options include Vigilon® (C.R. Bard, Inc, Covington, Ga), a commercially available sheet hydrogel marketed in the US for almost 25 years. This gelatinous sheet consists of an insoluble cross-linked polyethylene oxide copolymer with water as the dispersion medium. Its tensile strength and low-mass configuration make it susceptible to rapid evaporative loss (a removable, polyethylene film applied to one side of the dressing controls the rate of moisture loss). The product's clinical indications are limited to skin tears, minor chemical and thermal burns, cuts, abrasions, postoperative incisions and, most frequently, radiation dermatitis. Related literature limits its clinical applications to radiation dermatitis and postoperatively for cosmetic surgery. The product has not been prescribed for more extensive burn wounds. Other brands of hydrogel sheets — Nu-Gel™ (Johnson and Johnson, New Brunswick, NJ), Clear Site (Conmed Corporation, Utica, NY), Aquasorb (DeRoyal, Powell, Tenn), and Flexderm (Bertek [Dow Hickam] Sugar Land, Tex) — are used mainly as primary dressings for shallow wounds in specific anatomical areas. No reports about their use in major burn wounds are available. The study product choice was made with consideration to this information and the availability of the study product.

Methods

To address facility need, a clinical evaluation of sheet hydrogel used in place of porcine and cadaver skin was conducted. Senior medical and nursing staff in the burn unit made the decision to use hydrogel on all patients admitted to the burn service who would otherwise have been treated with either porcine or cadaver skin according to established protocols. The use of hydrogel sheets on other wounds — eg, skin graft donor sites — also was evaluated. In the context of evaluating a product already approved for wound care, IRB permission was not required. When appropriate, patients were informed that the dressing was used because of the lack of availability of the regular products. All dressing applications were performed by the burn unit staff (including burn unit nursing staff for ward dressings and burn unit medical staff for operating theater dressings). Objective and subjective pain assessment tools were used to monitor patient feedback: a visual analogue scale¹⁴ with a range of 1 to 10 was used for adults; the Wong Baker FACES Pain rating scale was used for children.¹⁵ The only change to existing protocol was the substitution of hydrogel sheets where porcine or cadaver skin would otherwise be used. Senior medical and nursing staff (including the author, Ward Manager, and Clinical Nurse Specialist) maintained oversight of all care and documentation procedures, which were detailed in the patients' medical records. Wounds were determined to be healed when the dressing could be detached without pain and the underlying skin was completely re-epithelialized.

Clinical Evaluation

The clinical evaluation of hydrogel in the author's facility included five types of traumatic and iatrogenic wound care challenges commonly encountered in clinical burn care: dressings for skin graft donor sites and acute partial-thickness burns as well as temporary dressings for excised full-thickness wounds, meshed autografts, and cultured cell applications.

Donor site dressing

In this evaluation, sheet hydrogel was first used on a split-thickness skin donor site on the left lower leg. The 14-year-old female patient had a history of extensive burn reconstructive surgery, which has previously been described.¹⁶ The donor site (6 cm x 10 cm) was covered with sheet hydrogel, absorbent gauze, and crepe (a cotton-weave retention bandage). The hydrogel was applied with a 2-cm margin overlapping normal skin. No exudate breakthrough occurred and the patient did not experience any postoperative donor site pain. The dressing was left undisturbed for 10 days and removed. The hydrogel had become dry and the absorbent gauze was somewhat adherent to it. When the gauze was removed, the dry, "crispy" hydrogel remained (see Figure 3a,b,c). The hydrogel was gently moistened (see Figure 4a,b) and the dressing peeled back to expose the healed donor site (see Figure 5a,b). The patient reported that she experienced no pain during this process.

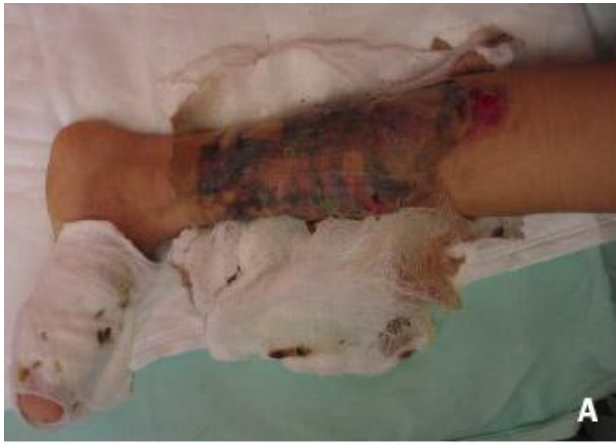


Figure 3. A) A small area of graft harvested from the left lower leg and the donor site dressed with hydrogel. The dressing was removed 10 days later. B) The hydrogel has become dry and "crispy." A hole has been made in the hydrogel cover. C) The donor site healed beneath the hydrogel.

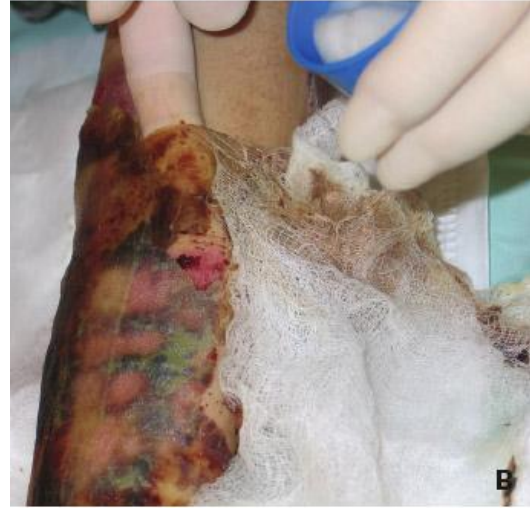
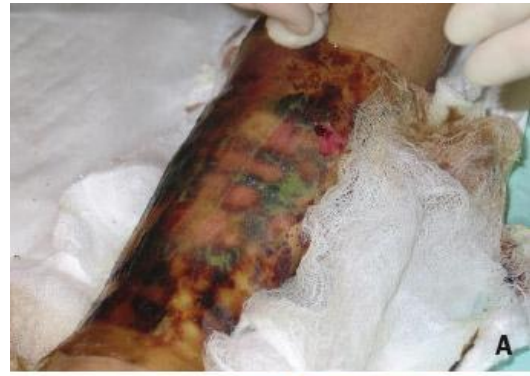
Figure 4. A) Adherence of dry hydrogel to the underlying, newly regenerated epidermis is reversed when moistened with saline to facilitate removal. B) Following rehydration, the "crisp" hydrogel became "plastic" in nature and a finger could be inserted under the hydrogel.

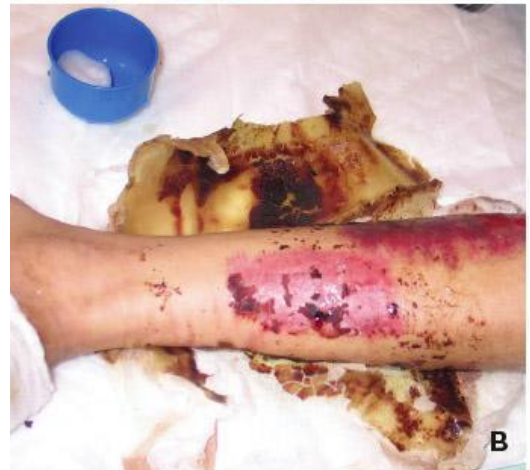
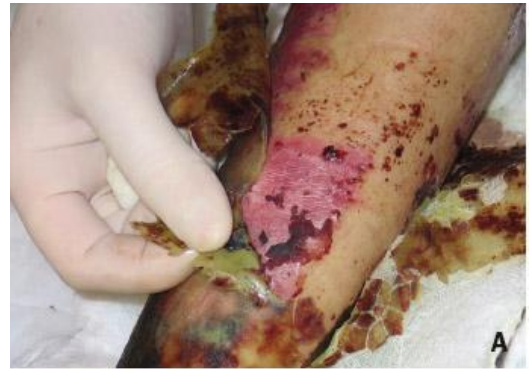
Figure 5. A) The hydrogel sheet could be cut with scissors and peeled back to reveal healed skin. B) A flat, dry, blood clot was evident on the surface of the skin.

Six subsequent patient experiences (10 donor sites) with hydrogel as a donor site dressing were uniformly favorable. Donor sites all healed within 10 days — a period within the normal range for the burn unit.¹⁷ A problem was noted only when the dressing was applied to larger donor site areas. The required larger sheets of hydrogel tended to slide on the fresh donor site, necessitating a generous overlap between the hydrogel sheets and on normal skin. Gauze dressing was wrapped over the hydrogel and securely fastened with a crepe retention bandage and tape (Omnifix® dressing retention tape, Hartman, Heideman, Germany).

Hydrogel versus calcium alginate dressings. A 73-year-old, otherwise healthy woman with scald burns to her trunk and lower left limb provided an opportunity to compare the hydrogel to a calcium alginate dressing (Kaltostat, Convatec Ltd, Deeside, UK) — one of numerous commercially available alginates used for burn management at the author's facility (see Figure 6a,b and Figure 7a,b). The patient had two donor sites, enabling her to compare both dressings. Both dressings needed to be soaked before removal. Although slightly more difficult to apply than the calcium alginate dressing — the nonadherent nature of hydrogel requires a retention dressing; the calcium alginate dressing adheres well to the donor site — the hydrogel sheet appeared to be as effective as calcium alginate with respect to time to healing and ease of removal and was less expensive (see Figure 8). The patient reported minimal pain with removal of both dressings.

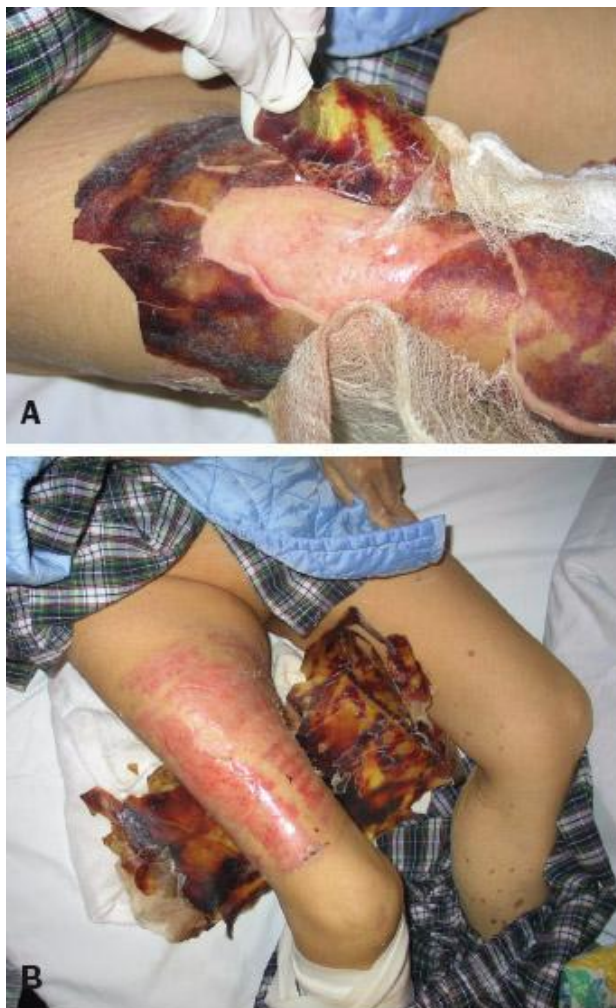

Figure 6. A) As more was learned about hydrogel, dressings were peeled back. B) The dry dressing separated easily and non-traumatically from the healed donor site.

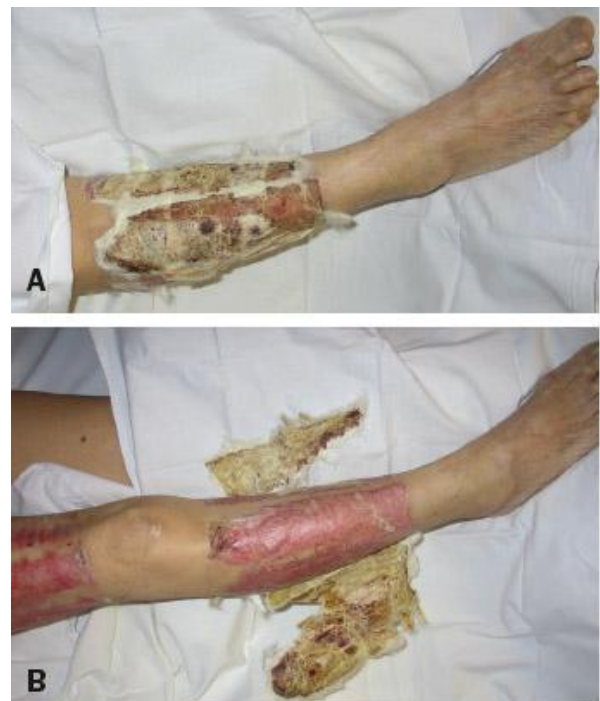

Figure 7. A) The patient's (see Figure 6a, 6b) right calf donor site was dressed with calcium alginate. B) This also dries into a "crisp" dressing that needs to be peeled off.

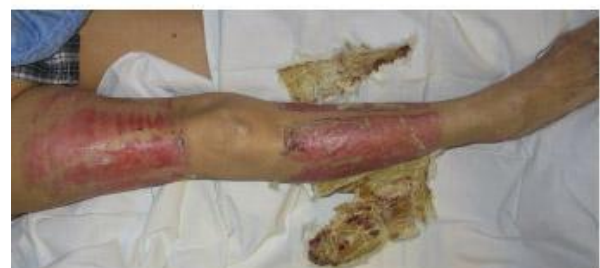

Figure 8. The two donor sites show equivalent healing.

Acute partial-thickness wounds. Hydrogel was applied to 10 non-exudative and six exudative wounds, including a facial burn wound. Facial burns are particularly challenging exudative wounds when patients have inhalation injuries and are intubated. It was found through experience that large sheets of hydrogel conform well to the wound beds and are quick and easy to apply. The wound can be readily inspected through the dressing and, in the unconscious ventilated patient, no retention dressing is necessary (see Figure 9a). In the case of a 23-year-old male patient who sustained a 70% body surface area (BSA) burn as a result of an explosion, the dressing was left in place for 48 hours. After 48 hours, the dressing had become swollen and exhibited a slightly yellow discoloration from absorbing the exudate. The underlying wound bed itself was dry (see Figure 9b). The patient's face went on to heal spontaneously and surgery was not needed. More frequent dressing changes may be necessary in the highly exudative wound. In the author's experience, the dressing should be changed daily until it becomes adherent to the underlying bed. In the superficial partial-thickness burn with little or no exudate, the first hydrogel dressing applied becomes dry and adheres to the wound. As the wound heals, the overlying hydrogel can be trimmed away (see Figure 10). The non-exudative wounds in this evaluation were all superficial partial-thickness wounds and healed within 10 days. The exudative wounds were assessed clinically (no biopsy or laser Doppler used) every 24 hours using wound history, appearance, and dressing change interval to predict healing, which is ultimately a function of depth of injury.¹ The exudative wounds were found to be deeper but all healed within 14 days following burn injury. Table 1 details the clinical management protocol for exudative and non-exudative partial-thickness burns that was developed during this evaluation period.

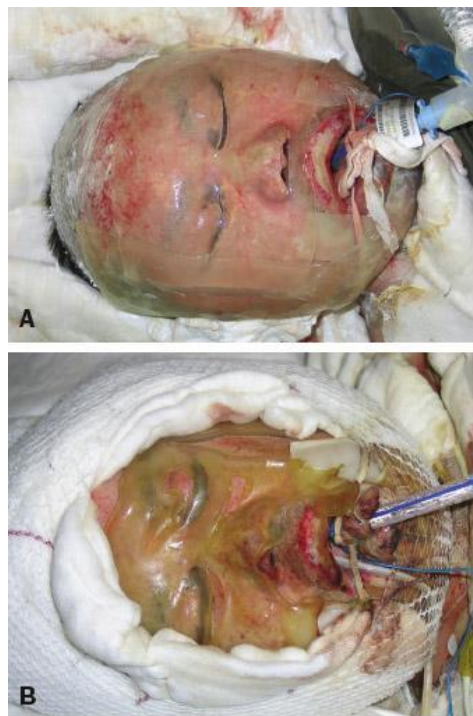

Figure 9. A) A large single sheet of hydrogel was applied to a highly exudative partial-thickness facial burn in a patient who required mechanical ventilation. B) Two days later, the dressing swelled with absorbed exudate and the underlying wound was dry.

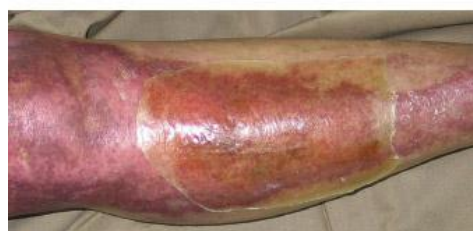

Figure 10. Hydrogel applied to a partial-thickness burn. The dressing adhered to the non-exudative wound. As the wound re-epithelialized, the hydrogel separated and gradually was trimmed back.

Full-thickness burn: temporary dressing. The author's facility utilizes a full-thickness burn care protocol of early excision (debridement that may involve removal of unburned tissue), requiring appropriate dressings to cover the surgical wound. The sandwich technique is used when enough autologous donor skin is available. This involves the application of widely meshed autograft to the wound bed following a full-thickness excision. Typically, the meshed skin is covered with cadaver allogenic skin to prevent desiccation of the wound bed in the interstices of the meshed graft. Hydrogel dressing also may be used in such situations (see Figure 11a,b,c). In the case illustrated (see Figure 12a,b), a 35-year-old female patient involved in an explosion had a 70% body surface area burn; 1:6 meshed autograft was applied and covered with hydrogel. Although 2 weeks later the hydrogel exhibited a yellow appearance, more than 70% of the graft had taken and the interstices of the autograft had re-epithelialized. When used with lower expansion ratios, graft take was found to be even more complete. In the same patient, hydrogel was placed directly onto an excised wound bed — a situation where cadaver skin would typically be used. The hydrogel was stapled to the wound bed to prevent movement. The hydrogel was not incorporated into the wound but it became swollen, indicating that it had absorbed exudate from the wound bed; in this circumstance, the cadaver skin yielded better results.

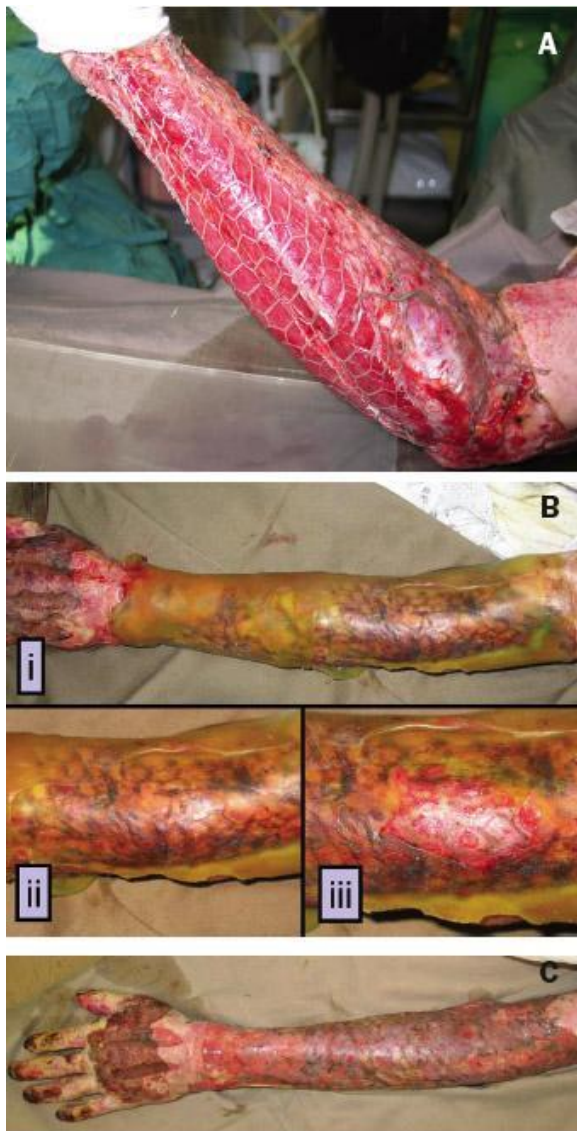


Figure 11. A) Extensive full-thickness burns are treated with early fascial excision and sandwich grafting where possible. A 1:6 meshed autograft was applied to the left forearm and covered with hydrogel. B) i: Two weeks later, the gel is dry and intact and has a yellowish appearance; ii: The hydrogel is transparent with underlying infection; iii: A hole in the hydrogel reveals the graft has taken and the interstices have re-epithelialized; C) The hydrogel was removed to reveal a 70% graft take for the entire forearm.

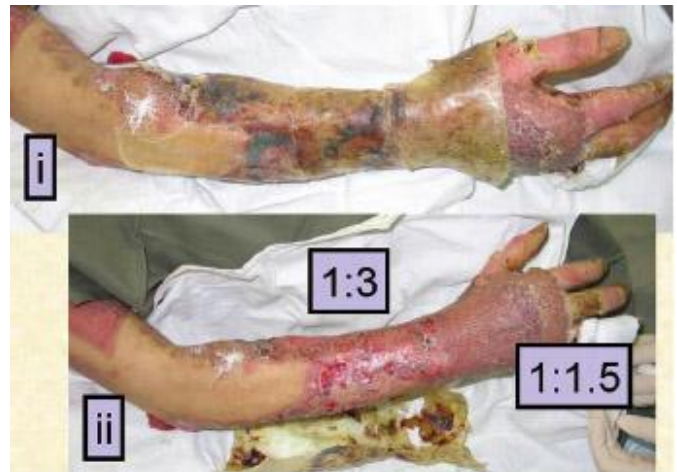

Figure 12. On the contralateral limb, sandwich grafting was used with 1:1.5 mesh over the hand with 100% graft take and over 1:3 mesh on the right forearm with 95% graft take.

Infection. In the first few cases of full-thickness wound excision, positive cultures, primarily for *Pseudomonas*, were collected from the wound bed(s). Because the hydrogel contains no intrinsic antibacterial agent, betadine or chlorhexidine-soaked gauze was applied over the hydrogel in subsequent cases. This modification was based on unpublished data from the author's laboratory experiments that examined the susceptibility of the bacterial flora found in the burns unit to topical antibacterial agents. Dressings were changed every 2 to 3 days and the wound bed remained healthy, viable, and non-infected, allowing further sandwich grafting once the first donor site wounds healed.

Cultured cells. Although cell suspensions are not often used in the author's practice, culture facilities are available. Cells are applied either to augment the take of widely meshed autograft or as *de novo* covering for an area of excised burn. A split-thickness skin biopsy is taken from an area of unburned skin and subjected to enzymatic separation of epidermis from dermis. The keratinocytes are suspended and expanded in culture — resultant cells can be applied as sheet grafts or cell suspension, which in this case was sprayed on the wound.¹⁸ The author's approach for covering cultured cell spray varies — either cadaver skin or Mepitel dressing (Molnlycke Heath Care, Norcross, Ga) can be used.¹⁹ The main goal is to allow the cultured cells to survive and proliferate *in situ*; a major concern is the possible cytotoxicity of dressing material, particularly silver-based dressings.⁷

It was of particular interest to see what would happen when cultured cells were applied to an abdominal wound in a patient with extensive burns whose wounds were covered with a hydrogel dressing (see Figure 13). The result was a 40% take of cells after 10 days. This compares favorably with published data¹⁸; however, the purpose was not simply to cover the area but also to prepare for a widely meshed autograft that was subsequently applied and helped facilitate complete wound closure.

Desloughing burns. Clinical experience has shown that some burns can be partially desloughed by changing porcine skin dressings and replacing them on a daily basis.² It was observed that hydrogel sheets have the ability to hydrate wounds and absorb exudate in deeper partial-thickness burns. In some wounds, the hydrogel swells but is not adherent. When the dressing is changed and the wound cleansed daily, the character of the wound changes — less slough and healthier granulation tissue is visible on the surface. After three to four daily dressing changes, the hydrogel became adherent (see Figure 14).

An ancillary observation made in the course of the evaluation was that symmetrical burns treated with either porcine skin or hydrogel sheets heal differently, with less inflammatory reaction and superficial scarring in the hydrogel treated burns, as noted in a 37-year-old woman who sustained bilateral scald burns to her upper limbs (see Figure 15a,b).

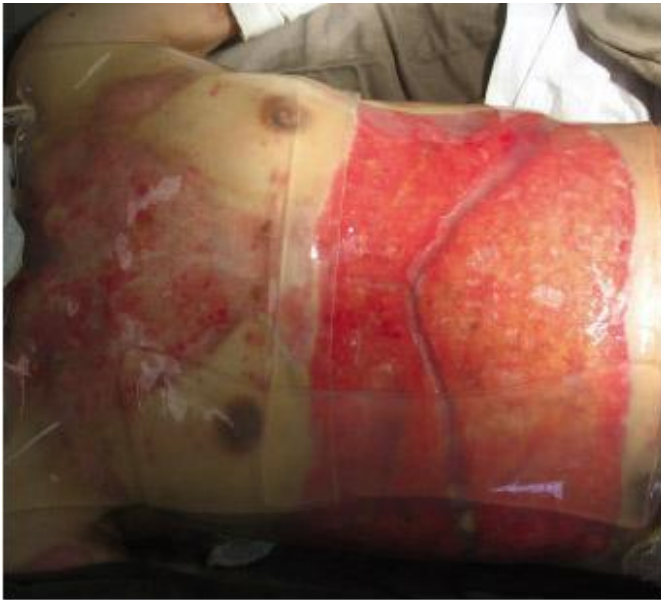

Figure 13. A patient with 65% body surface area flame burns. Hydrogel dressing was applied to partial-thickness wounds on the upper chest. The abdominal burn was full-thickness and had been excised. A cell suspension was applied and covered with hydrogel.

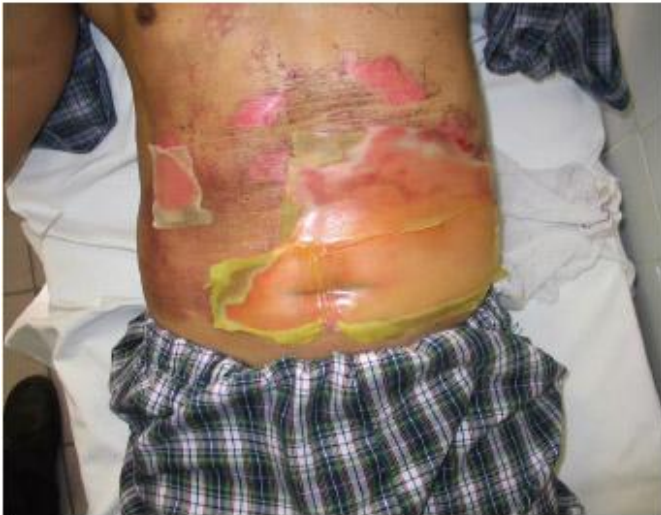

Figure 14. In exudative, partial-thickness burns, hydrogel can be changed on a PRN basis to control exudate and debride the wound. This patient's hydrogel dressing was changed daily for the first few days.

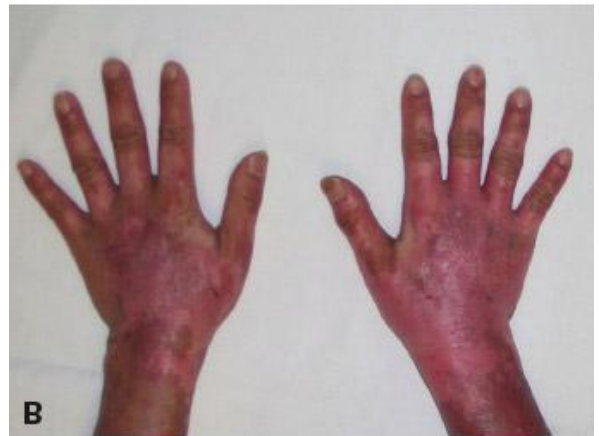
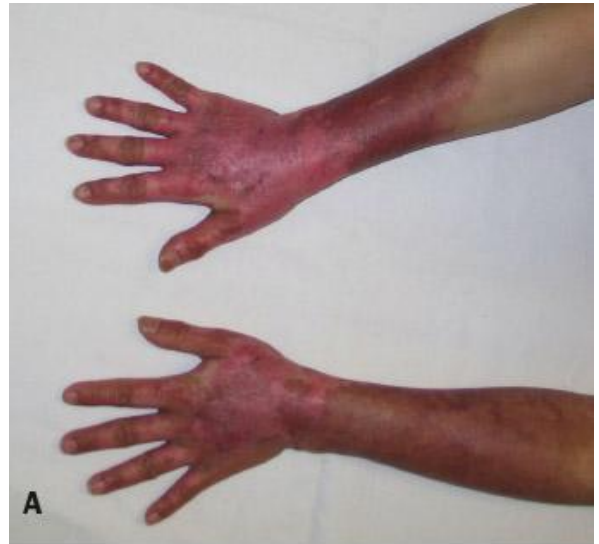
Figure 15. A) Bilateral forearm burns – one side has been treated with porcine skin and the other with hydrogel. Both healed within 10 days. B) Hydrogel was used on the left hand and porcine skin on the right. The working hypothesis is that the hydrogel treatment (left hand) causes less inflammatory reaction than the porcine skin dressing and that the scarring is related to the inflammatory stimulus.

Discussion

The cases described mirror the results observed in this initial clinical evaluation of more than 50 burn-related wounds in 30 patients. The hydrogel dressing was found to be comparable to existing standard treatments for donor sites and superficial partial-thickness burns. A Medline search specifically exploring the use of sheet hydrogels in burns care indicated a paucity of reports. Within the English language literature, only one clinical study, which examines the potential of using hydrogel and a semipermeable adhesive membrane in acute burns,²⁰ was published in the last 10 years. This report, however, discussed use of an amorphous, not a sheet hydrogel.

The safety and efficacy of hydrogels in general wound care have been well-established⁸ and no adverse events or reactions were observed in this clinical evaluation. In addition, the FDA has recognized the study product as a class 1 device; as such, it is exempt from the 510(K) Medical Device Pre-market Review Process and classified as a “Generally Recognized As Safe” (GRAS) device.

This initial clinical evaluation represents the first published report of the use of sheet hydrogels in comprehensive burn wound care. Initiated to respond to an unexpected crisis of biological dressing material availability, the evaluation was exploratory and designed to evaluate safety and usage, not efficacy. However, based on the author’s experience and comparison with historical controls, the performance of sheet hydrogels was as good as or better than porcine skin in superficial partial-thickness burns, alginates in donor sites, and cadaver skin in sandwich grafts. Research to substantiate these observations — specifically, prospective, blinded, randomized clinical studies — has been initiated.

Conclusion

Sheet hydrogel was found to be a successful substitute for porcine and/or cadaver skin in a variety of burn and burn-related wounds. The product performed well as a temporary dressing used as part of the sandwich technique, as a full-face dressing in ventilated burn patients, and to promote desloughing of partial-thickness burns. Hydrogel does not appear to stimulate an inflammatory response and facilitates burn preparation for surgical debridement. It is absorbent and well tolerated by patients who report no pain associated with the dressing change or between dressing changes. Disadvantages include the need for more than one person when applying large sheets and the fact that present formulations have no inherent antibacterial activity. Overall, hydrogel sheets seem to be a viable alternative or reserve dressing material for use in a range of burn-related wounds. In particular, hydrogel sheet dressings show potential for use in comprehensive burn wound management, a clinical area that warrants further research.

References:

1. Burd A, Chiu T. Allogenic skin in the treatment of burns. *Clin Dermatol.* 2005;23(4):376–387.
2. Chiu T, Burd A. “Xenograft” dressing in the treatment of burns. *Clin Dermatol.* 2005;23(4):419–423.
3. Burd A. Burn dressings. In: Wnek GE, Bowlin GL (eds). *Encyclopedia of Biomaterials and*

- Biomedical Engineering. New York, NY: Marcel Dekker, Inc;2004.
4. Shakespeare PG. The role of skin substitutes in the treatment of burn injuries. *Clin Dermatol*. 2005;23(4):413–418.
 5. Lang EM, Eiberg CA, Brandis M, Bjorn Stark GB. Biobrane in the treatment of burn and scald injuries in children. *Ann Plast Surg*. 2005;55(5):485–489.
 6. Burd A. Glycerolised allogenic skin: transplant or dressing? A Medico-legal question. *Burns*. 2002;28:S34–S39.
 7. Burd A, Kwok CH, Hung SC, et al. A comparative study of the cytotoxicity of silver-based dressings in monolayer cells, tissue explant, and animal models. *Wound Repair Regen*. 2007;15:94–104.
 8. Eisenbud D, Hunter H, Kessler L, Zulkowski K. Hydrogel wound dressings: where do we stand in 2003? *Ostomy Wound Manage*. 2003;49(10):52–57.
 9. Kiyozumi T, Kanatani Y, Ishihara M, et al. Medium (DMEM/F12)-containing chitosan hydrogel as adhesive and dressing in autologous skin grafts and accelerator in the healing process. *J Biomed Mater Res B Appl Biomater*. 2006;79:129–136.
 10. Parnell LK, Ciufi B, Gokoo CF. Preliminary use of a hydrogel containing enzymes in the treatment of Stage II and Stage III pressure ulcers. *Ostomy Wound Manage*. 2005;51(8):50–60.
 11. Christensen LH, Breiting VB, Aasted A, Jorgensen A, Kebuladze I. Long-term effects of polyacrylamide hydrogel on human breast tissue. *Plast Reconstr Surg*. 2003;111(6):1883–1890.
 12. Amin SP, Marmur ES, Goldberg DJ. Complications from injectable polyacrylamide gel, a new nonbiodegradable soft tissue filler. *Dermatol Surg*. 2004;30(12 pt 2):1507–1509.
 13. Qiao Q, Wang X, Sun J, et al. Management for postoperative complications of breast augmentation by injected polyacrylamide hydrogel. *Aesth Plast Surg*. 2005;29(3):156–161.
 14. Tengvall OM, Bjornhagen VC, Lindholm C, Jonsson CE, Wengstrom Y. Differences in pain patterns for infected and noninfected patients with burn injuries. *Pain Manage Nurs*. 2006;7(4):176–182.
 15. Wong DL, Hockenberry-Eaton M, Wilson D, Winkelstein ML, Schwartz P. Wong's Essentials of Pediatric Nursing, 7th ed. Available through: www.mosbysdrugconsult.com/WOW/faces.html. Accessed March 5, 2007.
 16. Burd A, Pang PC, Ying SY, Ayyappan T. Microsurgical reconstruction in children's burns. *J Plast Reconstr Aesthet Surg*. 2006;59(7):679–692.
 17. Ho WS, Ying SY, Choi PC, Wong TW. A prospective controlled clinical study of skin donor sites treated with a 1-4,2-acetamide-deoxy-B-D-glucan polymer: a preliminary report. *Burns*. 2001;27(7):759–761.
 18. Wood FM, Kolybaba ML, Allen P. The use of cultured epithelial autograft in the treatment of major burn injuries: a critical review of the literature. *Burns*. 2006;32(4):395–401.
 19. Burd A, Chan E. Keratinocyte-keloid interaction. *Plast Reconstr Surg*. 2002;110:197–202.
 20. Osti E. Cutaneous burns treated with hydrogel (Burnshield) and a semipermeable adhesive film. *Arch Surg*. 2006;141:39–42.